

# A Case of Empyema Necessitans Due to Interruption of Antituberculosis Treatment in Immunocompetent Patient

Amanpreet Kaur<sup>1</sup>, N. C. Kajal<sup>2</sup>, Amit Goyal<sup>1</sup>

<sup>1</sup>Junior Resident, Department of Chest and TB, GMCH Amritsar, BFUHS, Punjab, India.

<sup>2</sup>Professor, Department of Chest and TB, GMCH Amritsar, BFUHS, Punjab, India.

Received: August 2020

Accepted: August 2020

## ABSTRACT

Empyema necessitans (EN) (also sometimes spelled as empyema necessitatis) is a rare long term complication of empyema thoracis. It refers to extension of a pleural infection out of the thorax and into the neighbouring chest wall and surrounding soft tissues, e.g. extension of an empyema out with the pleural cavity. These cases result from inadequate treatment of an empyema and usually occur after a necrotizing pneumonia or pulmonary abscess. EN has become less common with the routine drainage of empyema and antibiotic use.

**Keywords:** Empyema Necessitans, Tuberculosis

## INTRODUCTION

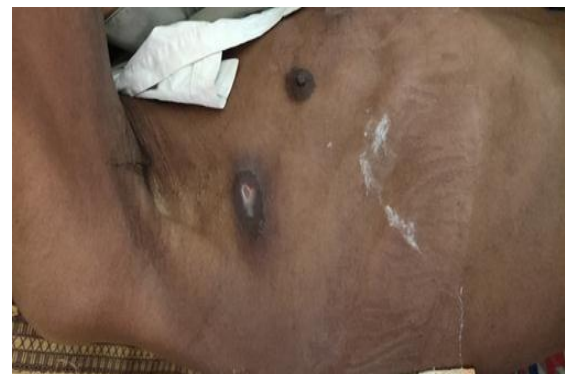Empyema necessitans is a clinical entity in which an intrathoracic empyema decompresses by extending itself through the parietal pleura and a weakness of the chest wall, forming a collection of pus in the extrathoracic soft tissues.<sup>[1-3]</sup> It occurs commonly to subcutaneous tissues of the chest wall, but can also spread to involve other sites such as the esophageal, breast, retroperitoneal, peritoneal, pericardial and paravertebral regions. Although rare, it can happen in the setting of necrotising pneumonia or pulmonary abscesses; the most common agents are *Actinomyces* spp. and *Mycobacterium tuberculosis*.<sup>[4]</sup> Tuberculosis account for ~70% of cases.<sup>[5]</sup> Regarding tuberculosis, this kind of complication can occur in the presence of pulmonary tuberculous empyema; it can also occur after an inadequate treatment of such empyema, like the obsolete surgical technique 'thoracoplasty' (resection of the postlateral aspects of the ribs, leading to the compression of the lung, collapse of apical lung cavities and pleural space obliteration. We present a rare case of young male who was diagnosed as a case of pulmonary TB now present with rare complication due to discontinuance of ATT.

## CASE REPORT

A 27yr male present with chief complaint of Cough with mild Expectorations, on and off fever and

breathlessness for last 2 months with associated complaint of discharging sinus in right infraxillary area for last 2 days which was previously a compressible swelling for last 4 months. There is no history of haemoptysis and Chest pain. Patient was diagnosed as a case of Pulmonary Tuberculosis but was lost to follow up for three months.

On examination patient was moderately built, respiratory rate is 29/min, PR 75/min, spo2 88% on air. On general examination Pallor and clubbing was present. Respiratory examination on inspection revealed a lump with discharging sinus on right lateral chest wall over the mid-axillary line with thick muddy yellowish discharge oozing out of it. [Figure 1].



**Figure 1: Showing a lump with discharging sinus on right lateral chest wall over the mid-axillary line with thick muddy yellowish discharge oozing out of it.**

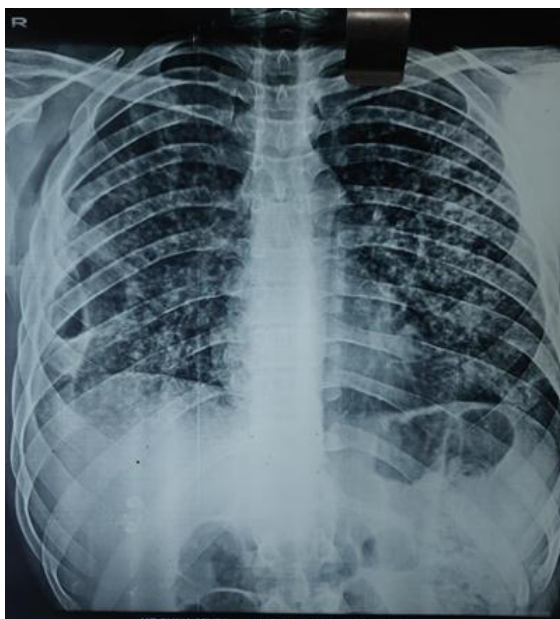
On auscultation bilateral coarse crepitation present with bronchial breathing over right infrascapular and infra axillary area (Amphoric in character).

Laboratory Findings show Hb 9.6gm, TLC 13200, ESR 110mm/hr, RBS 94, LFT and RFT with normal limit. HIV non-reactive Sputum for AFB: positive. Chest X-ray [Figure 2] 1 week before the discharge shows heterogeneous opacity in left side and air fluid level in right side.

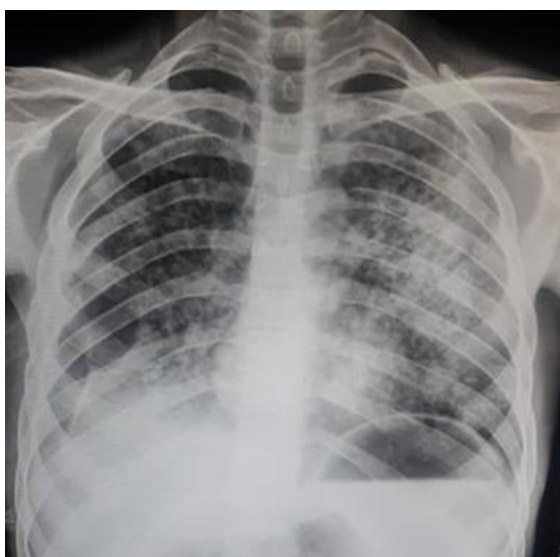
### Name & Address of Corresponding Author

Dr. Amanpreet Kaur  
Junior Resident,  
Department of Chest and TB, GMC Amritsar,  
Circular Road, Amritsar, Punjab.  
Email: ak1210.ap@gmail.com

The most recent X-ray [Figure 3] shows heterogenous opacity on left side with translucent pocket on right lower zone.



**Figure 2:** 1 week before the discharge shows heterogeneous opacity in left side and air fluid level in right side



**Figure 3:** Heterogenous opacity on left side with translucent pocket on right lower zone.

USG Chest revealed a Right side empyema (often relatively well demarcated collection) with extension through the chest wall into an extra-thoracic compartment.

So patient was diagnosed as a case of empyema necessitans, occurred due to complication of tubercular empyema and antitubercular treatment (ATT) interruption. To treat this, patient was again put on anti-tubercular drugs with drainage of abscess and aseptic dressing of the discharging sinus was done.

## DISCUSSION

Empyema necessitans (EN) is a rare manifestation of tuberculous (TB) infection. The exudative fluid in pleural cavity tracks down making fistula and manifests as a subcutaneous collection, where the patient can present with a chest wall lump.<sup>[6]</sup> Confirming the diagnosis of a tuberculous infection is difficult because of the paucibacillary nature of the lesion. Treatment interruption to anti-TB treatment (ATT) can lead to this complication. Anterior chest wall between midclavicular and anterior axillary line and between the second and sixth intercostal spaces is the commonest site to develop EN. Other recognized sites are bronchus, vertebral column, diaphragm, breast, mediastinum, retroperitoneum, esophagus, pericardium, flank, or groin.<sup>[7]</sup> The most common causative agent is *Mycobacterium Tuberculosis*, and *actinomyces* is the next most likely, other causes are *Streptococcus pneumoniae*, *Blastomycosis*, *Aspergillus*, *Nocardia*, *Mucormycosis*, *Fusobacterium*. Differential diagnosis of the chest wall mass includes benign and malignant soft tissue tumours, soft tissue infection or abscess and skeletal lesions.<sup>[8]</sup> Treatment of EN requires closed or open drainage of the pleural space to prevent fibrosis and to facilitate expansion of the lung. Appropriate antibiotic therapy is also a mainstay of treatment.<sup>[9]</sup> Our patient is treated by putting on ATT along with aseptic dressing of discharging sinus and closed drainage of pus with the needle.

## CONCLUSION

Empyema necessitans (EN) is a rare complication of tuberculosis infection. Reported cases in the literature describe patients presenting with chest wall lump of EN in the initial presentation in immunocompromised patients or with a more virulent infection in immunocompetent patients. EN has been reported among immunocompetent patients also with the most common cause being identified as the TB bacterium.<sup>[10]</sup> Other reported cases among immunocompetent patients were because of the virulence of organism such as *Staphylococcus aureus* (MSSA and MRSA) and *Actinomyces*. Treatment interruption for TB infection will lead to rare but serious complications like EN. Surgical drainage combined with ATT is the most effective method of treatment for EN. Before Antibiotics Era, mortality was very high among those with tuberculosis as the causative agent.

## REFERENCES

1. McNulty NJ. Reactivation *Mycobacterium tuberculosis* presenting as empyema necessitans 55 years following thoracoplasty. *Radiology case reports*. 2008 Jan 1;3(3):183.
2. Sahn SA, Iseman MD. Tuberculous empyema. *In Seminars in respiratory infections* 1999 Mar (Vol. 14, No. 1, p. 82).

3. Kono SA, Nauser TD. Contemporary empyema necessitatis. *The American journal of medicine*. 2007 Apr 1;120(4):303-5.
4. Llamas-Velasco M, Domínguez I, Ovejero E, Pérez-Gala S, García-Diez A. Empyema necessitatis revisited. *European Journal of Dermatology*. 2010 Jan 1;20(1):115-9.
5. Choi JA, Hong KT, Oh YW, Chung MH, Seol HY, Kang EY. CT manifestations of late sequelae in patients with tuberculous pleuritis. *American Journal of Roentgenology*. 2001 Feb;176(2):441-5.
6. Gamage D, Galagoda G, Palihawadana P. Impact of rubella vaccination on elimination of congenital rubella syndrome in Sri Lanka: progress and challenges. *WHO South-East Asia Journal of Public Health*. 2015;4(2):189-96.
7. Moh IH, Lee YK, Kim HJ, Jung HY, Park JH, Ahn HK, Noh JW, Han DH, Kim DM, Ihm SH, Choi MG. Email citations. *Tuberc Respir Dis*. 2014 Aug;77(2):94-7.
8. David EA, Marshall MB. Review of chest wall tumors: a diagnostic, therapeutic, and reconstructive challenge. *In Seminars in plastic surgery* 2011 Feb (Vol. 25, No. 1, p. 16). Thieme Medical Publishers.
9. Hockensmith ML, Mellman DL, Aronsen EL. *Fusobacterium nucleatum empyema necessitans*. *Clinical infectious diseases*. 1999 Dec 1;29(6):1596-8.
10. Holman R, Megally MN, Webster P, Warshawsky M, Awerbuch E. Medically managed empyema necessitans from *Mycobacterium tuberculosis* in an immunocompetent host. *In C61. Tuberculosis Case Reports* 2017 May (pp. A6004-A6004). American Thoracic Society.

**Copyright:** © Annals of International Medical and Dental Research. It is an open-access article distributed under the terms of the Creative Commons Attribution Non-Commercial License, which permits unrestricted non-commercial use, distribution, and reproduction in any medium, provided the original work is properly cited.

**How to cite this article:** Kaur A, Kajal NC, Goyal A. A Case of Empyema Necessitans Due to Interruption of Antituberculosis Treatment in Immunocompetent Patient. *Ann. Int. Med. Den. Res.* 2020; 6(5):PM04-PM06.

**Source of Support:** Nil, **Conflict of Interest:** Nil.