

# Evaluation of Effects of Pre-Emptive Sub-Mucosal Injection of Dexamethasone versus Methylprednisolone on Post-Operative Sequelae Following Third Molar Surgery-A Comparative Clinical Study

Mubashir Younis<sup>1</sup>

<sup>1</sup>Fellow Craniomaxillofacial Trauma (AOMSI), Department of Oral and Maxillofacial Surgery, Elite Mission Hospital, Thrissur, Kerala, India.

Received: July 2020

Accepted: July 2020

## ABSTRACT

**Background:** The purpose of this study was to evaluate and compare the effects of a single pre-operative dose of sub-mucosal dexamethasone and methylprednisolone on post-operative pain, swelling and trismus following mandibular third molar surgery. **Methods:** 40 healthy patients with Pell and Gregory's Class II Position B impacted mandibular third molars requiring surgical extraction were included in the study. The patients were randomly placed into two groups\_ A and B of 20 patients each. After the onset of local anesthesia, 4 mg of dexamethasone and 40 mg of methylprednisolone were administered sub-mucosally in Group A and Group B patients respectively. The surgical procedure was carried out using a standard surgical protocol. Baseline facial measurements and mouth opening were recorded pre-operatively. Post-operative assessment of pain, facial swelling and trismus was done at 2nd, 4th and 7th post-operative days and compared among the two groups and statistically evaluated. **Results:** Pre-operative baseline facial measurements and maximal mouth opening were comparable between the two groups ( $p > 0.05$ ). Statistically significant differences were noted between the two groups in terms of facial swelling and trismus on 2nd and 4th post-operative days ( $p < 0.05$ ) with dexamethasone group showing better results but there were no statistically significant differences observed when evaluation was done on 7th post-operative day. Group A had lower VAS scores but there was no statistically significant difference among the two groups regarding pain controlling ability. **Conclusion:** Pre-emptive sub-mucosal administration of dexamethasone effectively reduces post-operative sequelae when compared to methylprednisolone and improves quality of life after third molar surgery.

**Keywords:** Pre-emptive, dexamethasone, methylprednisolone, sub-mucosal.

1

## INTRODUCTION

The removal of impacted third molars is one of the most commonly performed minor oral surgical procedures. It involves trauma to adjacent soft and hard tissues leading to an inflammatory cascade in the postoperative period subsequently causing pain, swelling and trismus. These symptoms affect the quality of life in the immediate post-operative period.<sup>[1-3]</sup> To counter these post-operative sequelae, corticosteroids have been used widely.<sup>[4,5]</sup> Postoperative inflammation following surgical injury occurs due to the action of phospholipase A2 that converts phospholipids into arachidonic acid and the results in the synthesis of prostaglandins, leukotrienes, or tromboxane which act as mediators of the inflammation. Corticosteroids act in the initial phase of inflammatory cascade by inhibiting the enzyme Phospholipase A2 thereby inhibiting the production of these vasoactive substances and

decreasing post-operative inflammation.<sup>[6,7]</sup> The symptoms are not observed immediately but peak during 2<sup>nd</sup> day after surgery.<sup>[8]</sup> Corticosteroids may cause complications like stomach discomfort, indigestion, tachycardia, nausea, insomnia, metallic taste in the mouth, but it all depends on the dose and mode of administration of the drug. Prolonged use can cause delayed wound healing and increase patient's susceptibility to infections. However, in third molar surgery, the doses are given for shorter duration, hence chances of adverse effects are quite rare.<sup>[9]</sup>

Most of the studies usually compare the effect of a single corticosteroid against a control group or compare the effect of different routes of administration of the same corticosteroid. The aim of our study was to compare the effect of dexamethasone and methylprednisolone on the post-operative sequelae as to see which drug among the two provides better results following mandibular third molar surgery.

## MATERIALS & METHODS

The study was conducted in the Department of Oral and Maxillofacial Surgery after being approved by the local ethical committee. 40 healthy patients were included in the study with no co-morbidities and

### Name & Address of Corresponding Author

Dr. Mubashir Younis,  
Fellow Craniomaxillofacial Trauma (AOMSI),  
Department of Oral and Maxillofacial Surgery,  
Elite Mission Hospital Thrissur,  
Kerala, India  
Email: mubashiryounis3@gmail.com

having Class II Position B impacted mandibular third molars according to Pell and Gregory Classification. Patients aged less than 18 years, immunocompromised patients, patients with known drug allergies, those on existing antibiotic, analgesic or steroid use, pregnant and lactating females and those with other debilitating diseases were excluded from the study. All the patients were informed about the study and a written consent was obtained. The patients were randomly allocated to Group A (Dexamethasone group) and Group B (Methylprednisolone group) using computer generated table of random numbers, each group consisting of 20 patients.

Patients were asked to rinse the oral cavity with 0.12% chlorhexidine mouthwash. Anesthesia was achieved by giving ipsilateral inferior alveolar, lingual and long buccal nerve blocks using 2% lignocaine with 1:100000 adrenaline as local anesthetic solution. After achieving complete anesthesia, 4 mg dexamethasone or 40 mg methylprednisolone was injected into the buccal submucosa just buccal and distal to the third molar keeping the needle parallel to the occlusal plane. The patients were asked to wait for 15 minutes before the start of the procedure. Standard Ward's incision was used, full thickness mucoperiosteal flap was reflected and buccal guttering was done up to the cemento-enamel junction of the impacted third molar using straight handpiece and bur. The tooth was sectioned if required and removed completely. The socket was irrigated with normal saline and hemostasis was achieved. The flap was approximated and sutured with 3-0 vicryl. Time of surgery was recorded in each patient as the time elapsed from the first incision given to the last suture placed. Standard post-operative instructions were given to the patients and all the patients were prescribed Amoxicillin 500 mg 8 hourly and Ibuprofen 400 mg 8 hourly for 5 days. Patients were instructed to practice good oral hygiene using chlorhexidine mouth rinse thrice daily.

**Assessment of parameters:**

Post-operative pain, swelling and trismus were measured on 2nd, 4th and 7th post-operative days. Pain was measured by a 10 point visual analogue scale (VAS) in which 0 indicated no pain and 10 indicated worst possible pain. The amount of analgesics taken by the patient during the same period was also noted.

Baseline facial measurements were recorded pre-operatively with the help of measuring tape and similarly post-operative extraoral swelling was recorded as the sum of the length of two lines, one from tragus to corner of mouth and the other from lateral canthus of eye to angle of mandible.

Maximal mouth opening was recorded as distance between upper and lower incisors when mouth was opened to maximum. Trismus was taken as the

difference between this reading before and after surgery.

**RESULTS**

The recorded data was compiled and entered in a spreadsheet (Microsoft Excel) and then exported to data editor of SPSS Version 20.0 (SPSS Inc., Chicago, Illinois, USA). Numerical data was expressed as mean and standard deviation (SD) values. Student's independent t-test and Chi-square test were employed for comparing continuous and categorical variables respectively. Wilcoxon test was used for nonparametric numerical data and a p value of less than 0.05 was considered statistically significant.

**Table 1: Comparison of duration of surgery and number of analgesic tablets consumed**

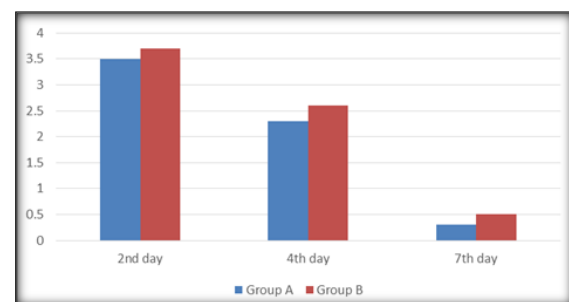
	Group A mean ± SD	Group B mean ± SD	p value
Duration of surgery in minutes	28.1 ± 4.13	27.4 ± 3.96	0.587
Analgesics consumed	11.7 ± 2.03	12.3 ± 2.17	0.372

**Table 2: Comparison of post-operative swelling at different stages**

Day of evaluation	Group A mean ± SD	Group B mean ± SD	p value
2nd Day	5.25 ± 4.98	9.37 ± 5.85	0.021
4th Day	3.78 ± 3.90	7.03 ± 5.01	0.028
7th Day	0.43 ± 1.99	1.12 ± 2.02	0.283

**Table 3: Comparison of decrease in mouth opening at different stages**

Day of evaluation	Group A mean ± SD	Group B mean ± SD	p value
2nd Day	-11.87 ± 6.73	-18.11 ± 8.27	0.013
4th Day	-11.22 ± 5.42	-17.56 ± 6.86	0.002
7th Day	-5.01 ± 4.83	-5.68 ± 5.14	0.637



**Figure 1: Comparison of Post-operative VAS score**

The mean duration of surgery in Group A and Group B was 28.1 minutes and 27.4 minutes respectively and no statistically significant difference was seen between the two groups (p = 0.587). The amount of analgesics consumed was compared between the two groups and there was no statistically significant difference noted (p = 0.372) [Table 1]. Although pain scores were relatively lower in the

dexamethasone group as compared to methylprednisolone group at all study days but the difference was statistically insignificant ( $p > 0.05$ ) [Figure 1]. Maximum swelling was observed on 2nd post-operative day in both the groups but Group A values were considerably lower than that of Group B and statistically significant differences were noted at 2<sup>nd</sup> and 4<sup>th</sup> days between the two groups ( $p = 0.021, 0.028$ ). The swelling gradually subsided by 7th post-operative day with no significant difference between the two groups ( $p = 0.283$ ) [Table 2]. Trismus was noted in both the groups at all the stages. This post-operative reduction in mouth opening was more in patients receiving methylprednisolone and when compared to dexamethasone, the difference was statistically significant ( $p = 0.013, 0.002$  at 2nd and 4th days respectively). The mouth opening almost returned to normal by 7th post-operative day [Table 3]. Wound healing was uneventful in all the patients from both the groups with no evidence of infection or dry socket.

## DISCUSSION

Glucocorticoids are quite often used in surgical practice because of their anti-inflammatory properties. They can be classified according to their duration of action as short, intermediate, and long acting. Cortisol and cortisone are examples of short-acting glucocorticoids, methylprednisolone is an intermediate-acting glucocorticoid whereas dexamethasone and betamethasone are long-acting glucocorticoids.<sup>[10]</sup> Corticosteroids are given at doses greater than the basal level of cortisol secretion in the body to achieve optimum anti-inflammatory effect. Therefore, in our study 4 mg dexamethasone and 40 mg methylprednisolone doses were employed based on previous data available.<sup>[11,12]</sup> Pre-operative administration was chosen based on previous studies which showed a better outcome with pre-emptive administration of the drug than when given post-operatively.<sup>[5,13,14]</sup> We opted for sub-mucosal administration as the injection technique is quite simple, less invasive, does not require special expertise or additional armamentarium and is convenient for the surgeon and the patient.<sup>[15,16]</sup>

There was no significant reduction in pain in the immediate post-operative period in either group. The possible reason for this may be the subsequent production of neurotransmitters like Substance P and Glutamate from the nociceptors in the spinal cord causing central sensitization of pain and, therefore the local production of prostaglandins and bradykinins which are inhibited by corticosteroids may not be the sole cause of post-operative pain.<sup>[12,17]</sup> VAS scores showed no significant differences between the two groups and there was no significant effect on the amount of analgesic consumed. Our results are in accordance with other

similar studies.<sup>[1,9,18,19]</sup> Extraoral swelling following third molar surgery results from the release of vasoactive substances which cause fluid transudation and edema. It has a slow onset and reaches peak during 48 hours after the surgery. Dexamethasone group showed better reduction in the size of swelling in our study as compared to the methylprednisolone group which may be attributed to the longer half-life of the drug.<sup>[1,20]</sup>

Trismus may occur as a reaction to pain alone or to pain in combination with muscle stiffness. Fluid transudation within the muscles of mastication adjacent to the surgical site may lead to muscle stiffness.<sup>[12]</sup> Reduction in mouth opening was observed less with dexamethasone as compared to methylprednisolone which can be again due to longer duration of action of dexamethasone. Swelling and trismus were noted maximum during 2nd post-operative day, reduced gradually and faded away by the end of 7<sup>th</sup> day. Similar results were noted in other studies as well.<sup>[1,21]</sup>

## CONCLUSION

Pre-operative submucosal injection of dexamethasone proved to be significantly more effective than methylprednisolone in reducing post-operative swelling and trismus. However, there was no significant difference in pain controlling ability between the two drugs. Based on the results of our study, we conclude that a single dose of dexamethasone given at the surgical site more effectively counters post-operative sequelae and improves quality of life following third molar surgery. However, further studies using other corticosteroids in different dosages and different routes are needed to achieve more reliable results.

## REFERENCES

1. Grossi GB, Maiorana C, Garramone AR, et al. Assessing postoperative discomfort after third molar surgery: a prospective study. *J Oral Maxillofac Surg* 2007; 65:901.
2. McGrath C, Comfort MB, Lo EC. Changes in life quality following third molar surgery—the immediate postoperative period. *Br Dent J* 2003; 194(5):265-261.
3. Savin J, Ogden GR. Third molar surgery—a preliminary report on aspects affecting quality of life in the early postoperative period. *Br J Oral Maxillofac Surg* 1997; 35:246-253.
4. Baxendale BR, Vater M, Lavery KM. Dexamethasone reduces pain and swelling following extraction of third molar teeth. *Anaesthesia* 1993; 48(11):961-4.
5. Klongnoi B, Kaewpradub P, Boonsiriseth K, Wongsirichat N. Effect of single dose preoperative intramuscular dexamethasone injection on lower impacted third molar surgery. *Int J Oral Maxillofac Surg* 2012; 41(3):376-9.
6. Flower RJ, Blackwell GJ. Anti-inflammatory steroids induce biosynthesis of a phospholipase A2 inhibitor which prevents prostaglandin generation. *Nature* 1979; 278:456-459.
7. Claman HM. Glucocorticosteroids II: the clinical responses. *Hosp Pract* 1982; 18:143
8. Troullos ES, Hargreaves KM, Butler DP, et al. Comparison of non-steroidal anti-inflammatory drugs, ibuprofen and

- flurbiprofen, with methylprednisolone for acute pain, swelling and trismus. *J Oral Maxillofac Surg* 1990; 48:945.
9. Darawade DA, Kumar S, Mehta R, Sharma AR, Reddy GS. In search of a better option: Dexamethasone versus methylprednisolone in third molar impaction surgery. *J Int Oral Health* 2014; 6(6):14-7.
  10. Ngeow WC, Lim D. Do corticosteroids still have a role in the management of third molar surgery? *Adv Ther* 2016; 33:1105.
  11. Kang SH, Choi YS, Byun IY, Kim MK. Effect of preoperative prednisolone on clinical postoperative symptoms after surgical extractions of mandibular third molars. *Aus Dent J* 2010; 55:462-467.
  12. Lim D, Ngeow WC. A comparative study on the efficacy of submucosal injection of dexamethasone versus methylprednisolone in reducing postoperative sequelae after third molar surgery. *J Oral Maxillofac Surg* 2017; 75(11):2278-2286.
  13. Al-Shamiri HM, Shawky M, Hassanein N. Comparative assessment of preoperative versus postoperative dexamethasone on postoperative complications following lower third molar surgical extraction. *Int J Dent* 2017;1350375. doi:10.1155/2017/1350375.
  14. Herrera-Briones FJ, Prados Sanchez E, Reyes Botella C, Vallecillo Capilla M. Update on the use of corticosteroids in third molar surgery: Systematic review of the literature. *Oral Surg Oral Med Oral Pathol Oral Radiol* 2013; 116:e342.
  15. Al-khateeb TL, Marouf HA, Mahmmod MA. Clinical evaluation of dexamethasone vs methylprednisolone for reducing postoperative inflammatory sequelae following third molar surgery. *Saudi Dent J* 1996; 8(3):131–135.
  16. Majid OW, Mahmood WK. Effect of submucosal and intramuscular dexamethasone on postoperative sequelae after third molar surgery: comparative study. *Br J Oral Maxillofac Surg* 2011; 49(8):647–652. doi:10.1016/j.bjoms.2010.09.021.
  17. Chen L, Yang G, Grosser T. Prostanoids and inflammatory pain. *Prostaglandins Other Lipid Mediat* 2013; 58:104-105.
  18. Milles M, Desjardins PJ. Reduction of postoperative facial swelling by low-dose methylprednisolone. *J Oral Maxillofac Surg* 1993; 51:987.
  19. Nair RB, Rahman NMM, Ummar M, et al. Effect of submucosal injection of dexamethasone on postoperative discomfort after third molar surgery: a prospective study. *J Contemp Dent Pract* 2013; 14:401.
  20. Kim K, Brar P, Jakubowski J, Kaltman S, Lopez E. The use of corticosteroids and nonsteroidal antiinflammatory medication for the management of pain and inflammation after third molar surgery: a review of the literature. *Oral Surg Oral Med Oral Pathol Oral Radiol Endod* 2009; 107(5):630-40.
  21. Filho JRL, Maurette PE, Allais M, et al. Clinical comparative study of the effectiveness of two dosages of dexamethasone to control postoperative swelling, trismus and pain after the surgical extraction of mandibular impacted third molars. *Med Oral Patol Oral Cir Bucal* 2008; 13:E129.

**Copyright:** © Annals of International Medical and Dental Research (AIMDR). It is an open-access article distributed under the terms of the Creative Commons Attribution Non-Commercial License, which permits unrestricted non-commercial use, distribution, and reproduction in any medium, provided the original work is properly cited.

**How to cite this article:** Younis M. Evaluation of Effects of Pre-Emptive Sub-Mucosal Injection of Dexamethasone versus Methylprednisolone on Post-Operative Sequelae Following Third Molar Surgery-A Comparative Clinical Study. *Ann. Int. Med. Den. Res.* 2020; 6(5):DE14-DE17.

**Source of Support:** Nil, **Conflict of Interest:** None declared