

# A Study on Prevention of Infection and Non-Union in Compound Fractures.

K. Thulasiram<sup>1</sup>, K. J. Reddy<sup>2</sup>

<sup>1</sup>Assistant Professor, Department of Orthopedics, SVS Medical College, Mahbubnagar, Telangana.

<sup>2</sup>Head of Department, Department of Orthopedics, SVS Medical College, Mahbubnagar, Telangana.

Received: October 2017

Accepted: October 2017

**Copyright:** © the author(s), publisher. Annals of International Medical and Dental Research (AIMDR) is an Official Publication of "Society for Health Care & Research Development". It is an open-access article distributed under the terms of the Creative Commons Attribution Non-Commercial License, which permits unrestricted non-commercial use, distribution, and reproduction in any medium, provided the original work is properly cited.

## ABSTRACT

**Background:** An open fracture with extensive soft tissue defects still remains one of the most delicate and challenging problems in trauma surgery. Severe bone and soft tissue injuries produced by high velocity trauma have become one of the common causes of morbidity and mortality all over the world. The prevention of infection and non-union in open fractures has changed dramatically over the last 15-20 years mainly as a result of improved plastic surgery techniques, but also because orthopedic surgeons have become more aware of the importance of debridement and early soft tissue cover and are now less absorbed by the minutiae of fracture fixation. The goal in the prevention of infection and non-union in compound fractures is to preserve the limb that is more functional than an amputated limb with prosthesis. Achieving this goal requires the current and timely management of both the bone and soft tissue defects. Various methods are followed with their advantages and drawbacks. The main aim is to study the different modalities of prevention of infection and non-union in compound fractures and to present our experience of primary soft tissue covers in the prevention of infection and non-union in compound fractures.

**Methods:** In a prospective study conducted in the department of orthopedics of Guntur Medical College/ Government General Hospital, Guntur, Andhra Pradesh, 60 cases of open fractures from September 2010 to Oct 2012 were admitted. All the cases were treated as per protocol with thorough debridement and early skeletal stabilization and wound coverage, bone grafting whenever necessary and finally fracture loading in cast or ilizarov. Plastic Surgeons were involved early in all the flap covers. Cardiothoracic and Vascular Surgeons were involved in Grade IIIC injuries. Patient was followed up regularly every 4 to 6 weeks and fracture union was tested radiologically and clinically. Status of the soft tissue cover was noted. When sufficient union was present, fixator was removed and the limb was put in below knee functional cast brace. Patients were called up for regular follow-ups to review the progress. On follow up assessment was done recording the status of the wound, clinical and Radiological evidence of fracture union, range of mobility at knee and ankle joints, function of the limb and complications.

**Results:** Out of 60 cases selected for the study age ranging from 1 year to 70 year, maximum cases 33.33% were in the age group of 21-30 years and 45 patients (75%) were male and 15 (25%) were female group. Most of the injury was due to RTA which were 48 cases (82.5%). 15 cases (25%) were in Type I, 12 cases (20%) were in type II and 36 cases (55%) were in type III Gustilo-Anderson classification. As per anatomical distribution, 42 cases (70%) involved tibia, 8 cases (13.33%) involved femur, 6 cases (10%) involved humerus and 4 cases (6.67%) involved forearm bones. Skeletal stabilization was done by plaster in 6 patients (10%), external fixation in 36 patients (60%) and by internal fixation in 18 patients (30%). Primary closure was done in 10 cases (16.67%), delayed primary closure was done in 7 cases (11.67%), split skin grafting was done in 27 cases (45%), flap coverage was done in 8 cases (13.33%) and in 8 cases (13.33%) wound were left open and they healed. Complications included in the study were pin tract infection in 9 cases (15%), equines in 5 cases (8.33%), knee stiffness in 4 cases (6.67%), toe clawing in 2 cases (3.33%), Non union in 6 cases (10%), chronic osteomyelitis in 4 cases (6.67%) and shortening in 5 cases (8.33%). There was no neurovascular damage, compartmental syndrome, failure of fixation or amputation. Overall result in our study was excellent in 30 patients (50%), good in 20 patients (33.33%), fair in 6 patients (10%) and poor in 4 patients (6.66%)

**Conclusion:** From our study we concluded that majority of the compound fracture seen in leg and are due to road traffic accident. Males are more commonly involved than females. Most of the fractures are Type III Gustilo-Anderson. The External fixator is useful apparatus for early stabilization and early wound coverage in type III fractures. Internal fixation given excellent results in Type I & II fractures, similar that of closed fracture. Early debridement and wound coverage is the single most determinant of the fracture out come. Dynamization is useful for early union of fracture. Bone grafting is useful in case of delayed union for union of fractures. Complications like joint stiffness are best compared to conservative methods.

**Keywords:** Fracture, Infection.

## INTRODUCTION

An open fracture with extensive soft tissue defects still remains one of the most delicate and challenging problems in trauma surgery. Severe bone and soft tissue injuries produced by high velocity trauma have become one of the common causes of morbidity and mortality all over the world. The prevention of infection and non-union in open fractures has changed dramatically over the last 15-20 years mainly as a result of improved plastic surgery techniques, but also because orthopedic surgeons have become more aware of the importance of debridement and early soft tissue cover and are now less absorbed by the minutiae of fracture fixation<sup>1</sup>. Open injuries expose many tissues like bone, tendon, nerves and vessels which are all tend to at risk when left exposed<sup>2</sup>. Hence it is important to give wound cover as early as possible. Here distinction must be made between wound cover and the wound closure. While early coverage is advantageous, imprudent closure can result in disasters. Attempts at tight closure in swollen limb or in a limb with potential for swelling in 48 hours of post operative period can lead to many complications like skin necrosis, compartmental syndromes and increase in infection rate<sup>3</sup>. Primary flap cover may be given if initial debridement is adequate. It would be advisable here to give primary soft tissue cover in day 1 to cover the defect of the limb. The goal in the prevention of infection and non-union in compound fractures is to preserve the limb that is more functional than an amputated limb with prosthesis. Achieving this goal requires the current and timely management of both the bone and soft tissue defects. Various methods are followed with their advantages and drawbacks conservative management, pins and plaster, dynamic traction, primary internal fixation with IM nails or plates, functional bracing which are some of the traditional approaches. These range from external fixator application and simple skin grafting to complex micro-vascular techniques<sup>4</sup>. The main aim is to study the different modalities of prevention of infection and non-union in compound fractures and to present our experience of primary soft tissue covers in the prevention of infection and non-union in compound fractures.

### **Name & Address of Corresponding Author**

Dr. K. Thulasiram  
Assistant Professor,  
Department of Orthopaedics,  
SVS Medical College, Mahbubnagar,  
Telangana.

## MATERIALS AND METHODS

This study was a prospective study conducted in the department of orthopaedics of Guntur Medical

College/ Government General Hospital, Guntur, Andhra Pradesh. 60 cases of open fractures were admitted from September 2010 to Oct 2012. The main aim is to study the different modalities of prevention of infection and non-union in compound fractures and to present our experience of primary soft tissue covers in the prevention of infection and non-union in compound fractures. All the cases were treated as per protocol with thorough debridement and early skeletal stabilization and wound coverage, bone grafting whenever necessary and finally fracture loading in cast or ilizarov. After haemodynamic stabilization of the patient, wounds were thoroughly cleaned up with saline irrigation, dressed accordingly and splinted suitably. Detailed systemic examination of the patient and local examination of the wounds were done. Radiological examination of the limb was carried out. Along with classification of fractures, other details such as nature of the fracture and type of the wound were noted. Anti tetanus serum was given to badly contaminated wounds in addition to Tetanus injection. Patients were put on triple antibiotics of penicillin, aminoglycosides and metronidazole. Once the patient was fit for surgery, in the operation theatre, after induction of anaesthesia, wounds were cleaned once again and thorough debridement was carried out and swabs were collected for culture and sensitivity. Fracture was exposed and reduced and fixed by means of either external or internal fixation. The type of fixator constructed and number of pins inserted, depended up on the size of the fragment and degree of comminution to get the stable fixation of the fracture. Plastic Surgeons were involved early in all the flap covers. Cardiothoracic and Vascular Surgeons were involved in Grade IIIC injuries. The wounds and pin tracts were dressed regularly to prevent infection. Antibiotics were administered in all cases and changes were made according to the culture and sensitivity reports. Early active movements of the joints were encouraged and crutch ambulation was started when general condition of the patient permits. Patient was followed up regularly every 4 to 6 weeks and fracture union was tested radiologically and clinically. Status of the soft tissue cover was noted. When sufficient union was present, fixator was removed and the limb was put in below knee functional cast brace. Patients were called up for regular follow-ups to review the progress. On follow up assessment was done recording status of the wound, clinical and Radiological evidence of fracture union, range of mobility at knee and ankle joints, function of the limb and complications.

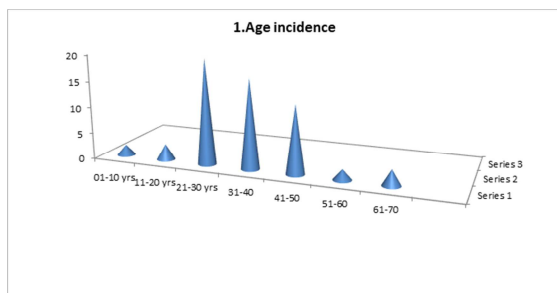
## RESULTS

From the data collected from the 60 cases selected for our study from September 2010 to October

2012, 3.33% cases were in the age group of 1-10 years, 5% cases were in the age group of 11-20 years, 33.33% cases were in the age group of 21-30 years. 28.33% cases were in the age group of 31-40 years, 21.67% cases were in the age group of 41-50 years, 3.33% cases were in the age group of 51-60 years and 5% cases were between 61-7- years of age group [Table 1] [Figure 1].

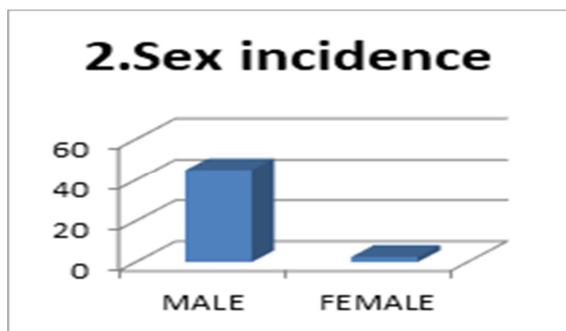
**Table 1: Showing age incidence.**

Age in years	No. of Cases	Percentage
01-10 yrs	2	3.33%
11-20 yrs	3	5%
21-30 yrs	20	33.33%
31-40 yrs	17	28.33%
41-50 yrs	13	21.67%
51-60 yrs	2	3.33%
61-70 yrs	3	5%



**Figure 1: Showing age incidence.**

Out of 60 patients, 45 patients (75%) were male and 15 (25%) were female group [Table 2] [Figure 2]



**Figure 2: Showing sex incidence**

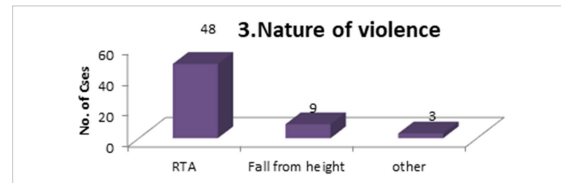
Most of the injury was due to RTA which were 48 cases (82.5%), 9 cases i.e. 15% were as a result of fall from height and other were 3 cases i.e. 5% [Table 3] [Figure 3]

**Table 2: Showing sex incidence**

Sex	No. of Cases	Percentage
Male	45	75%
Female	15	25%
Total	60	100%

**Table 3: SHOWING Nature of Violence**

Cause	No. of Cases	Percentage
RTA	48	80%
Fall from height	9	15%
Other	3	5%
Total	60	100%

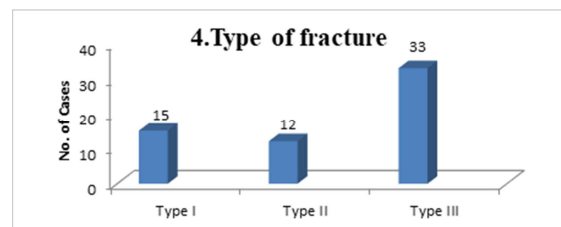


**Figure 3: SHOWING Nature of Violence**

Compound fracture was classified according to Gustilo-Anderson classification. 15 cases (25%) were in type I, 12 cases (20%) were in type II and 36 cases (55%) were in type III Gustilo-Anderson classification [Table 4] [Figure 4].

**Table 4: Showing Overall Functional Result**

	No. of Cases	Percentage
Type I	15	25%
Type II	12	20%
Type III	36	55%
TOTAL	60	100%

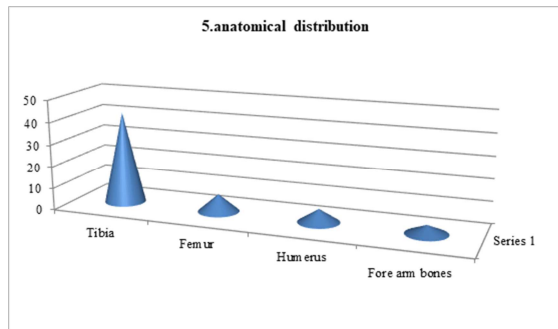


**Figure 4: SHOWING Type of Fracture (Gustilo-Anderson)**

As per anatomical distribution, 42 cases (70%) involved tibia, 8 cases (13.33%) involved femur, 6 cases (10%) involved humerus and 4 cases (6.67%) involved forearm bones [Table 5] [Figure 5].

**Table 5: Showing Anatomical Distribution**

	No. of cases	%	Sex				G.A. Classification					
			Male		Female		I		II		III	
			No	%	No	%	No	%	No.	%	No.	%
Tibia	42	70%	33	78.58%	9	21.42%	8	19.05%	8	19.05%	26	61.9%
Femur	8	13.33%	6	75%	2	25%	2	25%	2	25%	4	50%
Humerus	6	10%	4	66.67%	2	33.33%	2	33.33%	3	50%	1	16.67%
Fore arm bones	4	6.67%	2	50%	2	50%	2	50%	1	25%	1	25%

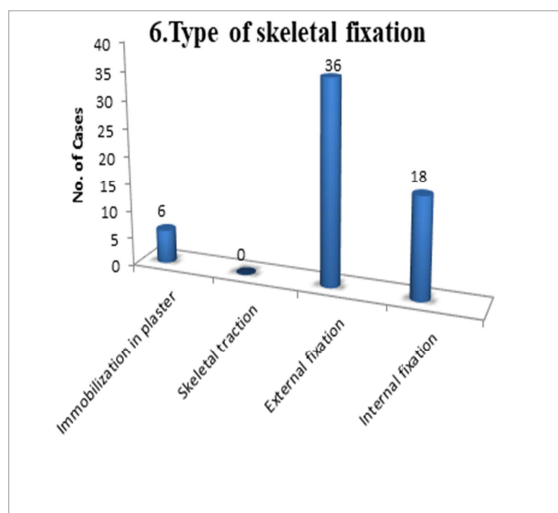


**Figure 5: Showing Anatomical Distribution**

Skeletal stabilization was done by plaster in 6 patients (10%), external fixation in 36 patients (60%) and by internal fixation in 18 patients (30%) [Table 6] [Figure 6].

**Table 6: Showing Type of Skeletal Stabilization**

	No. of Cases	Percentage
Immobilization in plaster	6	10%
External fixation	36	60%
Internal fixation	18	30%
Total	60	100%

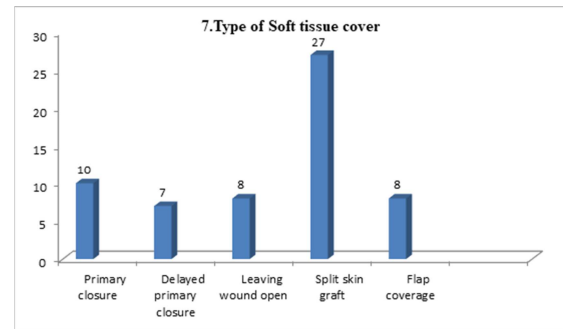


**Figure 6: Showing Type of Skeletal Stabilization**

Soft tissue management was done by various procedures. Primary closure was done in 10 cases(16.67%), delayed primary closure was done in 7 cases(11.67%), split skin grafting was done in 27 cases( 45%), flap coverage was done in 8 cases(13.33%) and in 8 cases (13.33%) wound were left open and they healed [Table 7] [Figure7]

**Table 7: Showing Type of Soft Tissue Cover**

	No. of Cases	Percentage
Primary closure	10	16.67%
Delayed primary closure	7	11.67%
Leaving wound open	8	13.33%
Split skin graft	27	45%
Flap coverage	8	13.33%
Total	60	100%



**Figure 7: Showing Type of Soft Tissue Cover**

Subsequent procedure included ilizarov in 4 cases (6.66%), free fibular graft in 3 cases (5%), LRS in 2 patients (3.33%) and plating in 1 patient (1.66%) [Table 8]

**Table 8: Showing Subsequent Procedure**

	No. of Cases	Percentage
Ilizarov	4	6.66%
Free fibular graft	3	5%
L.R.S	2	3.33%
Plating	1	1.66%

**Table 9: Showing Complications**

Complication	No. of Cases	Percentage
Pin track infection	9	15%
Contractures		
Equinus	5	8.33%
Knee stiffness	4	6.67%
Toe clawing	2	3.33%
Non-union	6	10%
Chronic Osteomyelitis	4	6.67%
Shortening	5	8.33%
Neurovascular damage	0	0%
Compartmental syndrome	0	0%
Failure of fixation	0	0%
Amputations	0	0%

**Table 10: Showing Overall Functional Result**

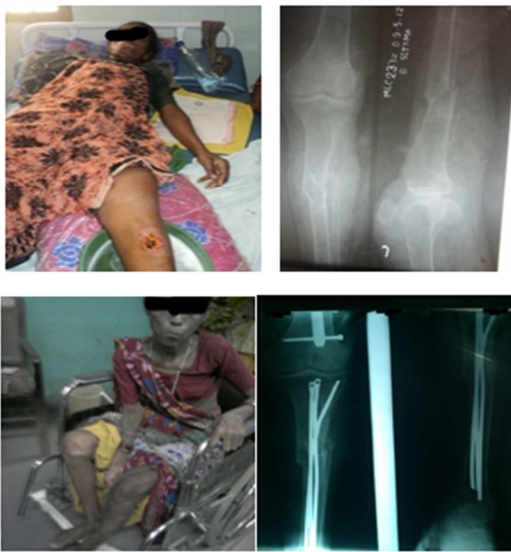Grade	Criteria	No. of Patients	Percentage
Excellent	Fracture united & soft tissue healed	30	50%
	No complication		
	Restoration of full function		
Good	Fracture united & soft tissue healed	20	33.33%
	Minimal joint stiffness		
	Minimal Angulation		
Fair / average	Delayed Union	6	10%
	Impairment of function		
	Infection		
Poor	Non-Union	4	6.66%
	Disability		
	Excessive loss of function		
Total		60	100%



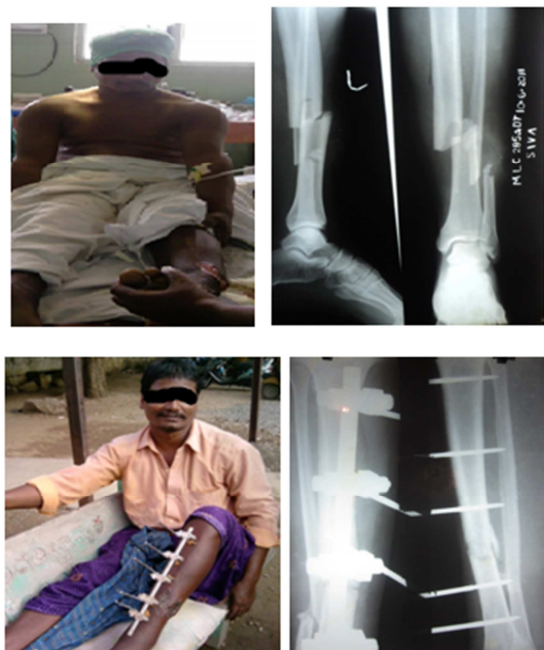Complications included in the study were pin tract infection in 9 cases (15%), equines in 5 cases (8.33%), knee stiffness in 4 cases (6.67%), and toe clawing in 2 cases (3.33%). Non union in 6 cases (10%), chronic osteomyelitis in 4 cases (6.67%) and shortening in 5 cases (8.33%). There was no neurovascular damage, compartmental syndrome, failure of fixation and amputation in the study [Table 9]

Overall result in our study was excellent in 30 patients (50%), good in 20 patients (33.33%), fair in 6 patients (10%) and poor in 4 patients (6.66%) [Table 10].

Below are shown preoperative and postoperative X-ray of operated patients [Case 1, 2].



**Case 1:** Preoperative X-ray of operated patients.



**Case 2:** Postoperative X-ray of operated patients.

## DISCUSSION

In the present study, we have studied 60 cases of open fractures from September 2010 to Oct 2012, which were admitted in GGH, Guntur. All the cases were treated as per protocol with thorough debridement and early skeletal stabilization and wound coverage, bone grafting whenever necessary and finally fracture loading in cast or ilizarov.

In our study the compound fracture were observed to be more common in the middle aged male. In our study, the minimum age was 11 year and maximum age was 70 years. The average age was 34.9 years. Out of 60 cases only 15 cases were females. The preponderance of the middle age group and occurrence in males can be explained by the nature of their activity and exposure to the vehicular and other accidents.

The commonest mode of injury was due to road traffic accidents (85%). Type III fracture constituted the majority of cases results from RTA. We have not included any vascular injury in our study. 50% of cases reported within 12 hours of injury for which primary debridement were done. Minimal soft tissue handling and thorough debridement was the aim during the operative procedure. Thorough irrigation of the wound with normal saline was proved to be useful. Most of the Type I and Type II open fracture were internally fixed and for most of the III fracture external fixator was applied. Majority of the fixator were uni-lateral and uni-planar type of frame construction.

Out of 60 cases of open fractures 42 (70%) are tibia, 8 (13.33%) are femur, 6 (10%) are humerus and 4 (6.67%) are both bones of forearm. In tibia and femur most of the fractures are of type III. 61.9% and 50% respectively. In humerus and forearm most of the open fractures belong to type I. Infection risks also differ by fracture type and have been reported to be ranging from 0 to 2% for Type I fractures, 2 to 10% for Type II fractures, and 10 to 50% for Type III fractures.<sup>5,6,7</sup> More recent studies have shown that the rates of clinical infection increased to 1.4% (7/497) for Type I fractures, 3.6% (25/695) for Type II fractures, and to 22.7% (45/198) of Type III fractures.<sup>8</sup> These data are similar to a more recent study on the treatment of open tibia fractures.<sup>8,9]</sup>

Early stabilization of open fractures provides many benefits to the injured patient. It protects the soft tissues around the zone of injury by preventing further damage from mobile fracture fragments. It also restores length, alignment, and rotation—all vital principles of fracture fixation. This restoration of length also helps decrease soft tissue dead spaces and has been shown in studies to decrease the rates of infection in open fractures.<sup>[10-12]</sup>

The fracture was stabilized in a week time in the most of cases. Healthy wound which were taken up early were sutured primarily. Lastly, early fixation allows improved access to soft tissues surrounding the injury and facilitates the patient's early return to normal function.<sup>[13]</sup>

Large one which were healthy, but could not be sutured were covered with SSG or flap cover. Out of 60 cases the wounds are covered with SSG in about 27 cases and primary closure in 10 cases and flap coverage in 8 cases. Benson et al assessed the benefit of delaying primary closure of the wound associated with open fractures.<sup>[14]</sup> Eighty-two fractures were divided into groups of primary closure (44 wounds) and delayed closure (38 wounds), on average 5 days after injury. Only 3 superficial wound infections were reported, having occurred in the primary closure wounds. Finally, Hertel et al performed a retrospective study of 29 open tibial fractures of type IIIA and type IIIB and found that immediate coverage was associated with a lower rate of infection: 0% (zero of 14),<sup>[15]</sup> as compared with 27% (4 of 15) after late coverage. Bone grafting is done in all cases of delayed union. Prophylactic bone grafting can also be used in the early treatment of open fractures. The literature has several examples of studies pertaining to immediate or early prophylactic bone grafting, and this practice has reported to shorten the time to fracture union and reduce the rate of delayed union by more than 11 weeks.<sup>[16-19]</sup>

6 cases of non-union are encountered, 2 cases are due to keeping the wound open and other 2 cases are gap non union. These are later treated by ilizarov technique.

The average time in which the patient is on fixator in between 8-10 weeks, after removal of fixator, a below knee functional cast bracing is applied. The average time taken for the fracture to unite is 14 weeks.

The complication observed are pin track infection 9 cases (15%) and loosening, treated by removal, curettage and antibiotics. Non-union occurred in cases (10%), chronic osteomyelitis in 5 cases (8.33%).

Comparative studies	Infection	Non-union
Gustilo - Anderson	2%	12%
Caudle et al	6%	9%
Cramer, Limbard, Green	2%	15%

The rate of infection of open fractures is associated with the fracture characteristics, antibiotics therapy and host parameters.<sup>[20,21]</sup> The infection risks differ by the type of fracture and they have been reported to be ranging from 0 to 2% for type I fractures, from 2 to 10% for type II fractures and from 10 to 50% for type III fractures.<sup>[22,23]</sup>

More recent studies have shown that the rate of clinical infection increased to 1.4% (7/497) for type

I fractures, 3.5% (25/695) for type II fractures and to 22.7% (45/198) for type III fractures.<sup>[20]</sup>

Out of 60 cases, the result was excellent in 30 (50%) good in 20 (33.33%), average in 6 cases (10%) and poor in 4 cases (6.66%).

## CONCLUSION

From our study we concluded that majority of the compound fracture seen in leg and are due to RTA. Males are more commonly involved than females. Most of the fractures are Type III Gustilo Anderson. The External fixator is useful apparatus for early stabilization and early wound coverage in type III fractures. Internal fixation given excellent results in Type I & II fractures, similar that of closed fracture. Early debridement and wound coverage is the single most determinant of the fracture outcome. Dynamization is useful for early union of fracture. Bone grafting is useful in case of delayed union for union of fractures. Complications like joint stiffness are best compared to conservative methods.

## REFERENCES

1. CM. Court - Brown: Intramedullary nailing of open fracture. AC-Masquelet and B. Scheweck: Principles of management of soft tissue injury in open fractures, 2007.
2. Charles C. Edwards M.D., Shelton C. Simmon M.D., Bruce Du Browner, M.D. and Mahstry C. weigel M.A. Severe open Tibial fractures Results treating 202 injuries with external fixation. Clinical Orthopedics and related research No: 230 May 1988.
3. Isreal Ziv M.D, F.R.C.S. (C) and David Segal M.D, Immediate Care of crush injuries and compartment syndrome with the split thickness skin excision. Clinical orthopaedics and related research No: 256 July, 1990.
4. Edmund Y.S.Chao Ph.D., Hannu. T. Arc. M.D. David G. Lewallen M.D., and Patrick J. Kelly M.D; The affect of rigidity on fracture healing in external fixation; Clinical Orthopaedics and related research No: 241 April 1989.
5. Maxwell and John E. Hoopes- Management of compound injuries of the lower extremity. Plastic and reconstructive surgery, February, 1979.
6. Burger, A.R.; Poka, A: Brumback, R.J and Bosse, M.J.: Management of open grade III tibial fractures. Ortho. Clin.of North America, Vol. 18, No.1 86-93, Jan. 1987.
7. Charnely Sir John, Compound Fracture and the Management of Wounds. A short practice of survey, Love and Baily, 16th Ed. 310, 1975, Edited by harding Rains H.J., David Ritche H.
8. Patzakis MJ, Wilkins J. Factors influencing infection rate in open fracture wounds. Clin Orthop Relat Res. 1989; 243:36-40.
9. Templeman DC, Gulli B, Tsukayama DT, Gustilo RB. Update on the management of open fractures of the tibial shaft. Clin Orthop Relat Res. 1998; 350:18-25.
10. Worlock P, Slack R, Harvey L, Mawhinney R. The prevention of infection in open fractures: An experimental study of the effect of fracture stability. Injury. 1994; 25:31-8.

11. Merritt K, Dowd JD. Role of internal fixation in infection of open fractures: Studies with *Staphylococcus aureus* and *Proteus mirabilis*. *J Orthop Res.* 1987; 5:23–8.
12. Merritt K. Factors increasing the risk of infection in patients with open fractures. *J Trauma.* 1988; 28:823–7.
13. Gustilo RB, Merkow RL, Templeman D. The management of open fractures. *J Bone Joint Surg Am.* 1990; 72:299–304.
14. Benson DR, Riggins RS, et al. Treatment of open fractures: A prospective study. *J Trauma.* 1983; 23:25–30.
15. Hartel R, Lambert SM, et al. On the timing of soft tissue reconstruction for open fractures of the lower leg. *Arch Orthop Trauma Surg.* 1999; 119:7–12.
16. Blick SS, Brumback RJ, Lakatos R, Poka A, Burgess AR. Early prophylactic bone grafting of high-energy tibial fractures. *Clin Orthop Relat Res.* 1989; 240:21–41.
17. Kesemenli CC, Kapukaya A, Subasi M, Arslan H, Necmioglu S, Kayikci C. Early prophylactic autogenous bone grafting in type III open tibial fractures. *Acta Orthop Belg.* 2004; 70:327–31.
18. Kobbe P, Frink M, Oberbeck R, Tarkin IS, Tzioupis C, Nast-Kolb D, et al., editors. Treatment strategies for gunshot wounds of the extremities. *Unfallchirurg.* 2008; 111:247–55.
19. Trabulsky PP, Kerley SM, Hoffman WY. A prospective study of early soft tissue coverage of grade IIIB tibial fractures. *J Trauma.* 1994; 36:661–8.
20. Patzakis MJ, Wilkins J. Factors influencing infection rate in open fracture wounds. *Clin Orthop Relat Res.* 1989; 243:6–40.
21. Bewen TR, Widmaier JC. Host classification predicts infection after open fracture. *Clin Orthop Relat Res.* 2005; 433:205–211.
22. Gustilo RB, Anderson JT. Prevention of infection in the treatment of one thousand and twenty five open fracture of long bones, retrospective and prospective analysis. *J Bone Joint Surg (Am)* 1976; 58-A: 453–458.
23. Gustilo RB, Gruninger RP, Davis T. Classification of type III (severe) open fracture relative to treatment and results. *Orthopedics.* 1987; 10:1781–1788..

**How to cite this article:** Thulasiram K, Reddy KJ. A Study on Prevention of Infection and Non-Union in Compound Fractures. *Ann. Int. Med. Den. Res.* 2017; 3(6):OR06-OR12.

**Source of Support:** Nil, **Conflict of Interest:** None declared