

Clinico Radiological Profile of Orbital Lesions Presenting to a Medical College in Himachal Pradesh, India.

Gaurav Sharma¹, Rajeev Tuli², Anil K Verma³, Mandeep Tomar³

¹Assistant Professor, Department of Ophthalmology, Dr RP Govt. Medical College, Kangra at Tanda.

²Professor, Department of Ophthalmology, Dr RP Govt. Medical College Kangra at Tanda.

³Senior Resident, Department of Ophthalmology, Dr RP Govt. Medical College Kangra at Tanda.

Received: August 2017

Accepted: August 2017

Copyright: © the author(s), publisher. Annals of International Medical and Dental Research (AIMDR) is an Official Publication of "Society for Health Care & Research Development". It is an open-access article distributed under the terms of the Creative Commons Attribution Non-Commercial License, which permits unrestricted non-commercial use, distribution, and reproduction in any medium, provided the original work is properly cited.

ABSTRACT

Background: To elucidate the clinical and radiological profile of patients with orbital disease presenting to the department of ophthalmology, Dr. RPGMC, Kangra at Tanda. **Methods:** The patients presenting with an orbital disease were subjected to a detailed clinical history and examination. This was followed by relevant blood investigations, radiological investigations best suited to the patient, based on our presumptive diagnosis. FNAC was done where the diagnosis was unclear even after radiological investigations. Appropriate treatment was then given to the patients. **Results:** Thirty patients i.e. 16(53%) Males and 14 (47%) females were included in the study. Out of them 19 (63%) were adults and 11 (37%) were children. These patients were divided into the following major diagnostic groups: Thyroid orbitopathy, (7, and 23.3%), Inflammatory lesions (5, 16.7%) Lymphoproliferative lesions (4,13.3%), Optic nerve tumors (3,10%), Metastatic Lesions (3,10%), Vascular neoplasms (2,6.7%), Vascular and structural lesions (2, 6.7%), Cystic lesions (2,3.3%), Mesenchymal lesions (1,6.7%), Others and unclassified (1,3.3%). The clinical and radiological features of these cases are discussed. **Conclusion:** A thorough clinical examination along with appropriate radiological investigation can help diagnose most of the orbital diseases with accuracy. The choice of radiological investigation depends on the presumptive diagnosis based on clinical evaluation supplemented with findings of the orbital B scan. CT scan is good diagnostic tool for most of the orbital diseases in particular inflammatory lesions as most cases have origin from the sinuses. Lympho- proliferative diseases and optic nerve lesions are particularly well imaged on MRI.

Keywords: Lympho-proliferative diseases, Orbit.

INTRODUCTION

Orbit is bony cavity which contains the eyeball, extra ocular muscles, nerves, blood vessels, lymphatics, and lacrimal gland, all of which are relatively protected by the bony walls of this cavity. Due to a variety of tissues present in the orbit and therefore orbital disease resulting by a pathology of any of these, it is truly a Pandora's Box of diseases. Orbital diseases most frequently present as proptosis, and along with it other signs like restricted ocular movements, audible bruit may be found in some cases. Orbital lesions may also be at times presenting sign of systemic diseases like metastatic cancers. A thorough work up of these cases is therefore required to arrive at a diagnosis. Historically; age of presentation, duration and progression are important clues to the possible etiology, and clinically;

Presence or absence of inflammatory signs, audible bruits, palpation of orbital margins, contribute significantly to tailor down the list of possible differential diagnosis. The above examination will guide the clinician to the relevant investigations which enable him to arrive at final diagnosis. B-scan ultrasonography, even conventional, can contribute significantly to the diagnosis before CT/MRI. FNAC of the orbital lesions, if done by a trained pathologist may be useful since the need for orbital biopsy may be obviated.

A study of orbital diseases in this belt of Himachal Pradesh was not undertaken previously to the best of our knowledge and therefore to understand the profile of these diseases we have undertaken this study, hoping that the results will help us in better management of these cases.

Aim

To elucidate the clinical and radiological profile of patients with orbital disease presenting to the department of ophthalmology, Dr. RPGMC, Kangra at Tanda.

Name & Address of Corresponding Author

Dr. Gaurav Sharma
Assistant Professor,
Department of Ophthalmology,
Dr RP Govt. Medical College, Kangra,
Tanda.

MATERIALS AND METHODS

Study Design

Retro-Pro prospective, observational, descriptive study

Study Duration: Two years

Study Population: Patients with orbital diseases presenting to department of ophthalmology

Inclusion criterion

All patients of any age and either gender were included the study

Methodology

The patients presenting with an orbital disease were subjected to a detailed clinical history and examination. This was followed by relevant blood investigations, radiological investigations best suited to the patient, based on our presumptive diagnosis were done. FNAC was done where the diagnosis was unclear even after radiological investigations. Appropriate treatment was then given to the patients.

Orbital diseases among pediatric patients and adults were entirely different with inflammatory lesions and pediatric tumors being commonest in children; thyroid related orbitopathies and lymph proliferative diseases predominating in adults.

The clinical characteristic of the lesions are as under. The radiological profile is given in the [Table 2]

RESULTS

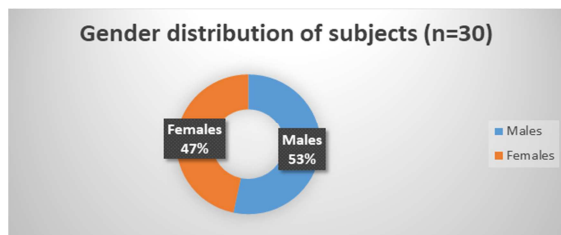


Figure 1: 16(53%) Males and 14 (47%) were females

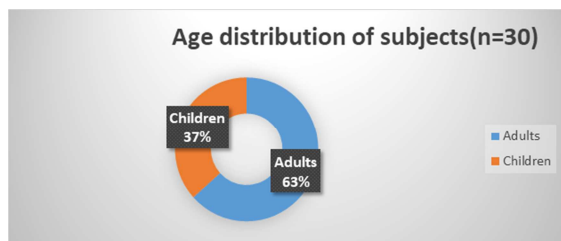


Figure 1: 19 (63%) were adults and 11 (37%) were children

Table 1: Distribution of cases according to major diagnostic groups

S.no	Diagnostic groups	Number of cases	Percentage
1	Thyroid orbitopathy	7	23.3
2	Inflammatory lesions	5	16.7
3	Lymphoproliferative lesions	4	13.3
4	Optic nerve tumors	3	10
5	Metastatic Lesions	3	10
6	Vascular neoplasms	2	6.7
7	Vascular and structural lesions	2	6.7
8	Cystic lesions	2	3.3
9	Mesenchymal lesions	1	6.7
10	Others and unclassified	1	3.3
	Total	30	100

1. Thyroid orbitopathy: Out of the six cases encountered by us, four were females (66.7%) .Two of them had hyperthyroidism while four were euthyroid at the time of presentation. Proptosis was the most common presenting complaint (5/6), followed by lid retraction (5/6) and restricted ocular movements (1/6), lid lag was observed in 5/6 cases.
2. Inflammatory lesions: Most cases of were of Orbital cellulitis. Three of them were children while one was an adult. Sinus disease was the primary cause in three, while the adult patient had sustained trauma with a retained intraorbital foreign body. The finding were consistent with those described in the previous studies. One female was diagnosed as having Idiopathic Orbital Inflammation. She presented with bilateral proptosis and conjunctival chemosis. There was past history of a similarly occurring proptosis in the past which resolved spontaneously. The patient showed dramatic response to steroids.
3. Cystic Lesions The only cystic lesion seen in the present study was a female with a palpable mass in the inferior orbit on the left side. B scan showed a cystic mass which could not be differentiated with the inferior rectus. One case of congenital cystic eye ball which is due to failure of the invagination of primary optic vesicle between 2-7 mm stage of fetal development. It was associated with cleft lip and palate. Imaging (B Scan and MRI) showed an orbital cyst.
4. Lymphoproliferative lesions: Out of the four lymphoproliferative lesions, one was a child who had acute myeloid leukemia and three were adults who had Benign Reactive Lymphoid Hyperplasia(BRHL). This was a 4 year old male child who presented with lid swelling gradually increasing since last 3 weeks and proptosis there was also conjunctival chemosis. Restricted ocular movements, 7th nerve palsy were additional features. His hemoglobin was 7.2 gm% and the total leucocyte count was 17,000/mm³. His differential leucocytic count showed 32.2% neutrophils, 47.8% lymphocytes and 19.8% monocytes. ESR was 41mm/hr.Peripheral smear showed immature cells possibly myeloblasts. The other three were adults who presented with slowly progressive painless abaxial proptosis and restricted ocular movements, one female also had ptosis. One of these patients underwent a B Scan guided FNAC and this showed benign reactive hyperplasia, based on which the diagnosis of BRLH was made. FNAC picture with following: Polymorphous lymphoid cell population comprised of mature lymphocytes, plasma cells, few

follicular center cells. Back ground shows lymph glandular bodies Reactive lymphoid hyperplasia.

- Vascular neoplasms: Lymphangioma in an 11 year old female child and capillary haemangioma in a 1 year old male child were the two vascular neoplasms encountered by us. The 11 year old girl with lymphangioma presented with gradually increasing proptosis of right eye. The swelling sometimes increased and decreased on its own. The other child had capillary haemangioma which was involving the

lid and also extending into the anterior orbit. Topical b Blockers resulted in significant reduction in the size of the lesions.

- Optic nerve tumors: Three patients of optic nerve tumors were seen. One was 11/2 year old female child with proptosis since 10 months which was gradually increasing over the period papilledema. There was RAPD on that side with edematous disc.^[11,12]

Table 3: Showing the Radiological profile of the lesions.

S. No	Type of the lesion	B Scan	CT/MRI
1	TRO	EOM enlargement with sparing of the tendons	Tendon sparing enlargement of the EOMs and orbital fat
2	Orbital cellulitis	Localised orbital mass with variable internal reflectivity and echo free areas in between	CT scan showed subperiosteal abscess in two cases with ethmoiditis
3.	Idiopathic orbital inflammatory disease (Myositic variant of the IOID.)	Enlargement of both lateral rectii, with involvement of the tendons	CT showed enhancing mass in both the lateral recti which was involving the tendons.
4	Optic nerve glioma	Intraconal mass with thickened optic nerve and negative 30 degree abduction test	Well defined fusiform soft tissue mass lesion sparing small retro-orbital segment approx. Lesion was hypo intense on T1W and hyper intense on T2W Waviness of the optic nerve, sheath space widening, posterior sclera flattening
5	Inferior rectus cysticercosis	Cystic lesion in the inferior orbit	The CT showed a cystic lesion in the inferior rectus and a diagnosis of inferior rectus cysticercosis was made.
6.	Acute myeloid leukemia	Echo free acoustic texture.	Extra conal mass between the roof of the orbit and the eyeball. The mass was slightly hyperintense to rectus muscle on T1W and T2W. Enhancement with central non enhancing area.
7	Benign reactive lymphoid hyperplasia	Variable internal reflectivity forming localised masses	Homogeneously enhancing soft tissue with displacement and insinuation between EOMs with encasement of optic nerve and with lacrimal gland involvement and remodeling of the lateral orbital wall
6	Capillary hemangioma	Ill defined lesion involving the superior orbit	Extraconal heterogenous lesion intense homogenous enhancement of causing inferomedial displacement of the globe
7	Lymphangioma	Cystic lesion in the superior orbit indenting the globe. Doppler showed a deep orbital mass with no vascularity which was not suggestive of orbital hemangioma.	Had fluid level Well defined enhancing cystic mass in the right orbit involving the intraconal and extraconal space
8	Cysticercosis of the inferior rectus	Cystic lesion in the inferior orbit	Cystic lesion of the right inferior rectus muscle displacing the globe superiorly
9	Congenial cystic eye ball	Cystic lesion with variable internal reflectivity	Cystic lesion in the right orbital area with no recognizable ocular tissue
10	Intraorbital migration of subperiosteal hematoma	-	Diffuse lesion arising from roof of the orbit Pushing the globe downwards
11	Cavernous sinus Thrombosis	-	The CT orbits showed a dilated superior ophthalmic vein on the right side
12	Post traumatic encephalocele	-	CT showed fracture of the superior orbital wall MRI picked up the encephalocele

13	Nasopharyngeal carcinoma	-	Nasopharyngeal mass invading the sinuses and displacing the orbit
14	Carcinoma of the maxilla	-	Mass lesion in the maxilla with destruction of the inferior orbital wall and invading the orbit displacing the globe superiorly
15	Rhabdomyosarcoma	-	Imaging showed a mass lesion diffusely involving the orbit, EOMs and the lids

DISCUSSION

The frequency of the major diagnostic groups was given by Rootman et al is almost the same as the orbital diseases encountered by us with the exception the Lymphoproliferative lesions which were seen by us more frequently as compared to the above studies. (18 % as compared to 5 %). Although thyroid orbitopathy (TRO) was also most frequently seen by us, its frequency was much lower (27% as compared to 50 %) as reported earlier.^[1,2]

The orbital muscles and fat were involved in TRO cases as reported in previous studies.^[3,4] We found that lid retraction and lag of adduction are particularly helpful in early diagnosis and fairly consistent signs. We encountered only one case of Idiopathic Orbital Inflammatory Disease, which was a myositic variant in a middle aged female. The CT usually shows diffuse involvement of the orbital tissues. However the myositic variant can be confined to one muscle as in our case.^[5-7]

Orbital involvement is a rare extramedullary manifestation of AML, with an estimated incidence of 2.5–8% in AML. Many cases the orbital involvement may precede the systemic manifestations of AML. The proptosis in these cases is mainly due to leukemic infiltrates, retro bulbar haemorrhage, orbital muscle infiltration or venous blockage. Peripheral smear is an invaluable tool in diagnosing the systemic form of AML showing immature blast cells with a high total leukocyte count and relative neutropenia. MRI shows slight hyper intensity on T1 and T2 weighted images and enhancement with contrast. Lymphomas, Benign Reactive Lymphoid Hyperplasia (BRLH), Plasma cell dysplasia, Leukemia and Histiocytosis are the common orbital lymphoproliferative diseases. BRHL is a benign proliferation of lymphoid follicles. A firm, rubbery mass is often palpable beneath the orbital rim, and there may be a pink subconjunctival 'salmon-patch' infiltrate. Final diagnosis requires biopsy.^[8,9]

Lymphangioma is a rare vascular hamartoma of lymphatic channels that is hemodynamically isolated from the vascular system. On CT it is low-density cystic, intra- and extraconal mass, with variable enhancement. There is no vascular component on angiography. On MRI the lesion is hypointense on T1; on T2 the signal is hyperintense but may be variable.^[10]

Subperiosteal migration of post traumatic supraorbital hematoma following manipulation has not been reported previously to the best of our knowledge. These cases can cause diagnostic problems even after orbital imaging as they often mimic orbital tumors arising from the roof of the orbit. Detailed history was helpful in establishing a correct diagnosis in this case.

Optic nerve gliomas had clinical and radiological profile in accordance with the profile in the literature.^[11,12]

CONCLUSION

A thorough clinical examination along with appropriate radiological investigation can help diagnose most of the orbital diseases with accuracy. Some times the orbital lesions have atypical presentation which may confuse the picture e.g myositic variant of IOID, or inflammatory signs in a case of Rhabdomyosarcoma. Lymphoproliferative diseases have variable clinical and radiological appearances which sometimes mimic IOID. Recognition of these subtle differences is essential for correctly diagnosing these conditions. The choice of radiological investigation depends on the presumptive diagnosis based on clinical evaluation supplemented with findings of the orbital B scan. CT scan is good diagnostic tool for most of the orbital diseases in particular inflammatory lesions as most cases have origin from the sinuses. Lymphoproliferative diseases and optic nerve lesions are particularly well imaged on MRI.

REFERENCES

1. Rootman JL. Diseases of the orbit. A multidisciplinary approach. Philadelphia, PA: JB Lippincott; 1988. p. 119–39
2. Shields JA, editor. Diagnosis and management of orbital tumors. Philadelphia, PA: WB Saunders; 1989. p. 291–315.
3. Sergott RC, Glaser JS. Graves' ophthalmopathy. A clinical and immunological review. *Surv Ophthalmol* 1981;26:1–21.
4. Bahn RS. Graves' orbitopathy. *N Engl J Med* 2010; 362:726–38.
5. Hornblase A, Herschorn BJ, Stern K, Grimes C. Orbital abscess. *Surv Ophthalmol* 1984; 29: 169-185
6. Bergin DJ, Wright JE. Orbital cellulitis. *Br J Ophthalmol*. 1986;70:174–8
7. Mannor GE, Rose GE, Moseley IF, Wright JE. Outcome of orbital myositis. Clinical features associated with recurrence. *Ophthalmology* 1997; 104: 409-414
8. Knowles DM II, Jakobiec FA. Ocular adnexal lymphoid neoplasms: clinical, histopathologic, electron microscopic, and immunologic characteristics. *Hum Pathol* 1982;13:148–62.

9. Ellis JH, Banks PM, Campbell RJ, et al. Lymphoid tumors of the ocular adnexa. Clinical correlation with the working formulation, classification and immunoperoxidase staining of paraffin sections. *Ophthalmology* 1985; 92:1311–24.
10. Rootman J, Hay E, Graeb D, Millar R. Orbital-adnexal lymphangiomas. A spectrum of hemodynamically isolated vascular hamartomas. *Ophthalmology* 1986;93: 1558-1570
11. Dutton JJ. Gliomas of the anterior visual pathways. *Surv Ophthalmol* 1993;38:427–52.
12. Listerick R, Louis DN, Packer RJ, et al. Optic nerve gliomas in children with NF-1: consensus statement for the NF-1 Optic Pathway Glioma Task Force. *Ann Neurol* 1997;141:143–9.

How to cite this article: Sharma G, Tuli R, Verma AK, Tomar M. Clinico Radiological Profile of Orbital Lesions Presenting to a Medical College in Himachal Pradesh, India. *Ann. Int. Med. Den. Res.* 2017; 3(6):OT01-OT05.

Source of Support: Nil, **Conflict of Interest:** None declared