

Healing of Extracted Socket after Surgical Removal of Impacted Mandibular 3rd Molar: A Comparison of PRP VS PRP with Bone Graft.

Bokhari K¹, Nada A², Jawaher A², Falah H², Ismail A²

¹Professor, Department of Dentistry, Government Medical College, Dimrapal, Jagadapur, Chattisgarh, India

²Nada Aied, Jawaher Assiri, Falah Huzzaim, Ismail Abdullah. Intern, College of Dentistry, King Khalid University, KSA.

Received: August 2018

Accepted: August 2018

Copyright: © the author(s), publisher. Annals of International Medical and Dental Research (AIMDR) is an Official Publication of "Society for Health Care & Research Development". It is an open-access article distributed under the terms of the Creative Commons Attribution Non-Commercial License, which permits unrestricted non-commercial use, distribution, and reproduction in any medium, provided the original work is properly cited.

ABSTRACT

Background: Platelet-rich plasma (PRP) is an autologous concentration of human platelets in a small volume of plasma. Because it is a concentration of platelets, it is also a concentration of the 7 fundamental protein growth factors proved to be actively secreted by platelets to initiate all wound healing. PRP contributes to better healing of soft tissues and bone and is a visible means of growth factor delivery. **Aims & Objectives:** a) To compare osteo-inductive capacity following surgical removal of impacted mandibular 3rd molar teeth b) to compare the difference in osteoinduction between PRP vs PRP + Bone Graft, c) Establish the potential benefits of these biomaterials in the regeneration of post-extraction alveolar bone. **Methods:** This is a prospective, randomized clinical trial involving 15 patients (split arch – 30 impacted molar teeth) who visited KKUCOD (Alsamer campus) for surgical removal of symptomatic impacted mandibular third molars. The study was conducted following due clearance from ethical and research committee of the institution (SRC/ETH/2016-17/004). The inclusion criteria included: Female patients aged between 18 and 45, b) Impacted mandibular third molar with similar anatomical position, and similar difficulty index. c Patient informed consent to carry out the intervention and for inclusion in the study. d) No allergies to medicines, non –smokers, non-alcoholics, no drug allergy and patients not under oral contraceptives. **Results:** The results are compiled as tables for different groups with percentage of bone formation at the end of week 1,3, 6 and at the end of 3rd months. There is not much difference in osteoinduction with the addition of PRP alone when compared to control side. However, addition of graft with PRP definitely enhances osteoinduction and makes a significant contribution in neo bone regeneration **Conclusion:** 1. PRP contributes significantly to osteogenesis when mixed with bone graft. 2. Healing is better when extracted sockets are supplemented with PRP. 3. There is no incidence of allergic reaction with the use of allogeneic bone grafts.

Keywords: Third molar surgery, graft, platelet rich plasma, osteoinduction.

INTRODUCTION

Research in dental and oral surgery often involves materials and procedures which are capable of improving clinical outcomes.^[1] Research is a dynamic, continuously evolving process which aims to improve clinical outcomes.

An impacted tooth is one that cannot, or will not erupt into its normal functioning position, and is therefore pathologic and requires treatment. 90% of the population have third molar teeth with at least 33% having one impacted third molar.^[2] Factors associated with bone loss following third molar extraction include age, direction of eruption,

preoperative bony defects and resorption of mandibular second molar root surface.^[3] Extraction of impacted teeth leads to a surgical defect with prolonged healing phase and bone formation. Platelet rich plasma (PRP) is a simple, cost effective procedure which initiates osteogenesis due to the presence of growth factors and proteins in it. An added benefit is absence of antigen – antibody reactions as the patient's own blood is processed as PRP and placed back into the extraction socket.

Application of PRP is varied and widely accepted. Since PRP has influence on both soft tissue and hard tissue regeneration, it is widely used in periodontal surgeries, maxillofacial surgeries, implant procedures. They are also of specific importance in patients whose healing capacity is retarded/delayed due to bisphosphonate use, old age/geriatric patients, post- radiation patients.

Platelet rich plasma (PRP) is an autologous source of platelet derived growth factors that enhance

Name & Address of Corresponding Author

Dr. Kamran Bokhari Syed,
Professor & HOD,
Department of Dentistry,
Government Medical College,
Dimrapal, Jagadapur,
Chattisgarh, India.

surgical soft and hard tissue wound healing.^[4,5] This concentrate of platelets containing various growth factors enhance osseous regeneration. The growth factors include 3 isomers of PDGF (platelet-derived growth factor), 2 of the numerous transforming growth factors (TGF-beta), the insulin like growth factor (IGF), the epithelial growth factor (EGF) and the vascular endothelial growth factor (VEGF), which are key elements in bone healing.^[6] The various forms of PRP include: pure PRP (P-PRP) or leukocyte –PRP (L-PRP).^[7] The growth factors get released from platelets of PRP. Degranulation and release of growth factors from platelets is initiated by activation of PRP with calcium chloride. Once activated, these growth factors play an important role in stimulating proliferation, chemotaxis and differentiation of cells essential for osteogenesis. PRP presents a low risk of infection or immunological reactions, as the platelets play an important role in host defense mechanisms. This is due to a signal peptide release which attracts macrophages.^[8] The osteoblastic proliferation role is due to morphogenic proteins which express markers of mineralization when incubated with preosteoblastic cells. Angiogenesis is explained by the role of TGF-b which favors production of fibronectin, a molecule involved in the adhesion of fibroblasts to the radicular surface thereby promoting angiogenesis.^[9-11] The study was conducted with the following aim & objectives: a) to compare osteo -inductive capacity following surgical removal of impacted mandibular 3rd molar teeth b) to compare the difference in osteoinduction between PRP vs PRP with bone graft, c) establish the potential benefits of these biomaterials in the regeneration of post-extraction alveolar bone, (d) to determine whether there are differences in the postoperative period depending on the material used.

MATERIALS AND METHODS

This is a prospective, randomized clinical trial involving 15 patients (split arch – 30 impacted molar teeth) who visited KKUCOD (Alsamer campus) for surgical removal of symptomatic impacted mandibular third molars. The study was conducted following due clearance from ethical and research committee of the institution (SRC/ETH/2016-17/004).

The inclusion criteria included: Female patients aged between 18 and 45, b) Impacted mandibular third molar with similar anatomical position, and similar difficulty index.c Patient informed consent to carry out the intervention and for inclusion in the study. d) No allergies to medicines, non –smokers, non-alcoholics, no drug allergy and patients not under oral contraceptives.

The study was conducted with the following aim & objectives: a) To compare osteo - inductive

capacity following surgical removal of impacted mandibular 3rd molar teeth b) to compare the difference in osteoinduction between PRP vs PRP + Bone Graft, c) Establish the potential benefits of these biomaterials in the regeneration of post-extraction alveolar bone, d)To determine whether there are differences in the postoperative period depending on the material used.

The patients were categorized into 3 groups

Group a: 5 patients (split arch – 10 impacted teeth): 5 control and 5 with PRP application Group b: 5 patients: (split arch – 10 impacted teeth): 5 control and 5 with PRP + graft Group c: 5 patients: (split arch – 10 impacted teeth): 5 PRP and 5 with PRP + graft

The surgical procedure was performed by a single operator. Technique and difficulty factor of impacted teeth (following Pell and Gregory classification) was almost similar.

Preparation of PRP

Under all aseptic techniques, 12 ml of venous blood was drawn through phlebotomy [Figure 1]. The collected blood was mixed with CPDA (0.8ml each).The sample was subjected to centrifuge at 2400 r.p.m. for 10 minutes. The supernatant formed is platelet poor plasma (PPP) and buffy coat. PPP and Buffy coat (upper1mm RB.C.) layer was transferred to a fresh vacutainer and again centrifuged at 3600 r.p.m.for 10 mins [Figure 2]. The upper half of the supernatant was discarded and the lower half was mixed thoroughly to yield platelet rich plasma (PRP).

The pre-processed PRP is taken into the sterile bowl and 0.5ml of CaCl₂ mixed to obtain the PRP gel, to be transferred to the surgical site [Figure 3]. Closure was done with 3-0 Mersilk.

Group with Graft: The collection of specimen, preparation of PRP remained to be the same. PRP in this group was mixed with allogenic calcium hydroxyapatite granules (GGG21, Surgiwear ISO 13485-2012). The graft with PRP was then transferred/placed into the extraction site. Primary closure obtained with 3-0 Mersilk.

All the patients were prescribed a routine course of antibiotic and analgesics for 5 days. Sutures were removed on the 7th post-operative day. Patient's were asked to report immediately if any allergic reactions such as erythema, itching, unusual swelling develop.

Assessment of bone formation was done by the following technique

a) Digital radiography (Sirona IOPA X ray machine) – IOPA x ray's were assessed for evidence of bone formation at the end of 1 week, 3 weeks, 6 weeks and 3 months. Standardization in taking IOPA radiographs was as follows: a) all the x-rays taken by single technician, using a single x-

ray machine, b) digital radiographs were assessed in the same computer by using the same software (R4). The X rays were taken using a bisecting angle technique following the same landmarks. Percentage of bone was measured using a standard scale and following measurements from the software provided in digital radiographs.

RESULTS

The results are compiled as tables for different groups with percentage of bone formation at the end of week 1,3, 6 and at the end of 3rd month. A consolidated table is then prepared to assess the values of control group, group with PRP and group with PRP and graft.

Finally, mean values are calculated for the three variables. i.e., control, PRP and PRP with graft. As shown in [Table 1], there is no significant difference in the percentage of bone formed between control site and PRP side at the end of weeks 1 and 3. However, at the end of 3 months, there is slight difference in the percentage of bone formed though not significant (10% difference in bone formation).

Table 1: Group a

Control Group (Right Side: #48)				
	1 week	3 weeks	6 weeks	3 months
Patient 1	1.5	5.6	12.8	62.2
Patient 2	0.8	4.8	15.1	71.2
Patient 3	1.1	5.5	16.3	66.9
Patient 4	1	5.1	13.5	65.7
Patient 5	1.8	4.3	14.4	63.5
Total	6.25	25.3	72.1	329.5
Mean Value (%)	1.25	5.06	14.42	65.9
With PRP (Left Side: #38)				
	1 week	3 weeks	6 weeks	3 months
Patient 1	2.4	5.2	13.9	66.7
Patient 2	2.1	4.4	16.7	79.8
Patient 3	1.9	6.7	19.1	81.2
Patient 4	1.1	7.2	17.3	76.4
Patient 5	0.7	5.5	17.4	71.3
Total	8.2	29	84.4	375.4
Mean Value (%)	1.64	5.8	16.88	75.08

Table 2: Group b

Control Group (Right Side: #48)				
	1 week	3 weeks	6 weeks	3 months
Patient 1	1.1	4.9	11.9	59.1
Patient 2	1.2	5.2	14.3	69.7
Patient 3	1.6	5.9	15.6	72.1
Patient 4	1.3	5.3	14.8	69.4
Patient 5	0.8	4.9	15.3	61.5
Total	6	26.2	71.9	331.8
Mean Value (%)	1.2	5.24	14.38	66.36
With PRP + Graft (Left Side: #38)				
	1 week	3 weeks	6 weeks	3 months
Patient 1	3.4	6.1	22.7	82.1
Patient 2	4.1	5.2	31.3	89.9
Patient 3	3.3	8.3	29.9	88.1
Patient 4	2.3	9.1	33.7	76.9
Patient 5	3.8	11.2	34.6	90.2
Total	16.9	39.9	152.2	427.2
Mean Value (%)	3.38	7.98	30.44	85.44

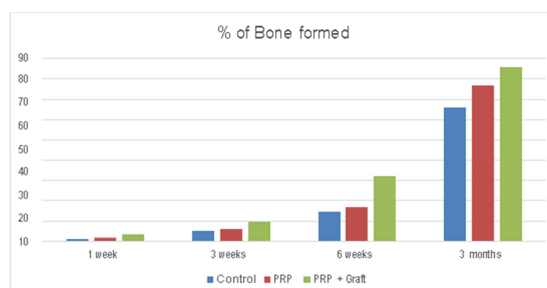
[Table 2] shows that there is significant difference in the amount of bone formed between control side and the side with PRP and bone graft particularly at the end of 6 weeks and 3 months. This co-relates with the fact that PRP with bone graft enhances osteoinduction.

Table 3: Group c

PRP (Right Side: #48)				
	1 week	3 weeks	6 weeks	3 months
Patient 1	3.1	5.8	12.8	72.1
Patient 2	1.8	5.6	16.7	77.7
Patient 3	2.6	7.6	17.8	78.9
Patient 4	2.2	5.4	18.2	81.2
Patient 5	0.7	4.8	16.6	80.1
Total	10.4	29.2	82.1	390
Mean Value (%)	2.08	5.84	16.42	78
PRP + Graft (Left Side: #38)				
	1 week	3 weeks	6 weeks	3 months
Patient 1	2.9	13.1	26.7	88.1
Patient 2	3.7	11.1	29.8	90.3
Patient 3	3.2	9.8	33.1	89.7
Patient 4	3.1	8.4	39.2	87.9
Patient 5	4.8	13.2	37.9	75.3
Total	17.7	55.6	166.7	431.3
Mean Value (%)	3.54	11.12	33.34	86.26

Table 4:

	1 week	3 weeks	6 weeks	3 months
Control	1.225	51.5	111	111.6
PRP	1.86	5.82	16.65	76.54
PRP + Graft	3.46	5155	6.115	1515



Graph 1: Percentage of Bone Formed

The influence of PRP with and without graft can be clearly assessed in [Table 3]. The results in [Table 3] shows that the presence of graft makes a significant difference in osteoinduction.

[Table 4] shows that there is not much difference in osteoinduction with the addition of PRP alone when compared to control side. However, addition of graft with PRP definitely enhances osteoinduction and makes a significant contribution in neo bone regeneration.

The difference in bone formation among the three groups was assessed by taking sequential radiographs and measuring the percentage of bone formed through R4 software. The amount of bone formation was recorded as millimeters and assessed in percentages. Difference in the percentage of bone formation among the three different groups was through descriptive analysis of the data and taking the mean values.

Graph 1 shows that bone formation is enhanced with addition of graft to PRP and the results are significant particularly at the end of 6 weeks.

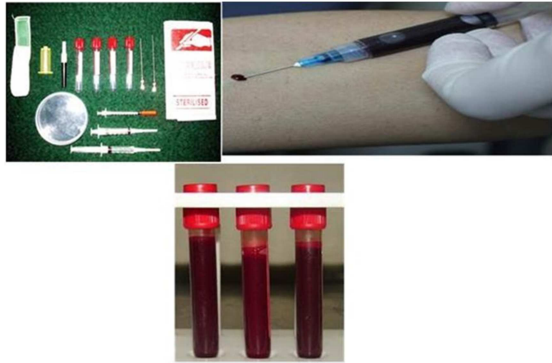


Figure 1: Collection of Venous Blood



Figure 2: Centrifugation

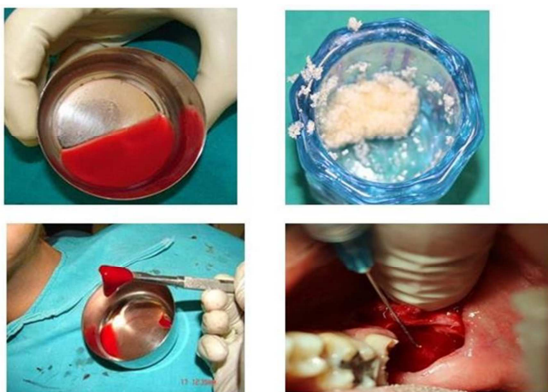

Figure 3: Graft Placement at the site

DISCUSSION

Platelet-rich plasma (PRP) is an autologous concentration of human platelets in a small volume of plasma.^[5] PRP is a valuable adjunct to promote healing following procedures such as mandibular reconstruction, repair of alveolar cleft, treatment of infrabony pockets, in conjunction with Osseo

integrated implants. PRP is also advisable in regions with suppressed healing tendencies such as post-radiation sites, areas prone for dry socket & osteomyelitis, sites with delayed osteogenesis such as fractures.

PRP provides approximately 2.16 increase in the maturation rate and considerably greater density of final bone – graft product.^[12] Few of the inherent characteristics of PRP include a) being biocompatible and biodegradable b) fibrin clot is absorbed within a few weeks of the wound healing process c) attributes to increased healing of wounds and surgical sites, which is correlated with less pain.^[13] PRP "jump-starts" osteogenesis by releasing growth factors which facilitates osteoblasts to move across a greater distance by creating a scaffold of fibrin¹⁴. Growth factors present in PRP are capable of forming a fibrin clot, thereby promoting fibroblast proliferation and up regulating collagen synthesis in the extracellular matrix¹⁵. Mineralization of the collagen matrix occurs more rapidly because PDGF is added right from the start in the mineralized bone segment of the graft, instead of being released from the collagen. As a result, PRP improves rate of bone formation by 1.62 to 2.18 times the normal bone healing time, improves trabecular bone density by 15% to 30%.^[12,14] When placed with graft, PRP improves the handling properties facilitating placement and stability.^{+[16]} This stability of graft allows the biologic elements to establish a foundation to activate and promote an environment conducive to graft survival.^[12] The most commonly used allografts are demineralized freeze-dried allograft (DFDBA) and freeze-dried bone allograft (FDBA). Nandakumar AS and Nandakumar K in 2006 stated that addition of PRP to allografts produces results similar to autogenous grafts in terms of osteoinduction potential.^[16] Osteoblasts are normally nonmotile cells and do not move greater than a distance of 0.4 mm. Once a scaffold is provided consisting of PRP and graft, osteoblasts tend to have a greater capacity of migration thus enhancing bone regeneration.^[12] Important contributions of PRP use were significant response to pain, improvement in swelling and better inter incisal opening following surgical removal of impacted third molar as reported by Ogundipe et al in 2011.^[17] Study conducted by Arenaz-Bua et al., in 2010 assessing the efficacy of PRP in promoting bone regeneration following third molar removal were not encouraging.^[18] Their results concluded that there was no enhanced osteoblastic activity following PRP use nor was there significant reduction in pain, swelling and trismus. Albanese A et al. in their systemic review suggested that the use of PRP in the alveolar socket following extraction is certainly capable of improving soft tissue healing but were not optimistic regarding enhanced bone

regeneration with the use of PRP.^[2] Though we have not assessed the soft tissue healing, incidence of dry socket, swelling and pain in this study, we have observed that the amount of swelling was significantly less with addition of PRP and PRP with bone graft. The healing along the suture line was also without a scar line when compared to control side. The incidence of dry socket was nil in this study.

Arenaz-Bua J et al., conducted a prospective, randomized, controlled, double blinded study to assess bone regeneration following surgical removal of impacted third molar teeth.^[18] They concluded that enhanced osteogenesis occurred in groups with the use of autologous bone and demineralized bone matrix and that PRP does not play a significant role in osteogenesis. The parameters used are similar to our study except that in the present study autologous bone graft was not used and bone formation was assessed through both digital radiography as well as CBCT. The results of the present study also suggest that there is no significant difference in osteogenesis with the addition of PRP alone. However, addition of graft to PRP has made significant contribution to bone regeneration. This must be due to the fact that though PRP has growth factors which are essential for osteogenesis, addition of graft makes a better "scaffold" for the osteoblasts to migrate and thereby contribute its role of osteoinduction. Therefore, in our opinion addition of graft provides as sort of mechanical "platform" which enables the osteoblasts produced from growth factors of PRP to migrate and form "neo-bone". Most of the studies conducted in literature have comparatively evaluated osteogenic potential of PRP with bone graft with control subjects. This present study comparatively evaluates three different groups such as PRP alone, control and PRP with bone graft. This establishes and differentiates a clear percentage among the variables.

Sammartino G et al., in their analysis of probing depth and periodontal; pocket formation following extraction of impacted mandibular third molars suggested that PRP is effective in inducing and accelerating bone regeneration for treatment of periodontal defects distal to second molar teeth.^[9] Similar studies also concluded that the periodontal pocket depth was reduced following application of PRP and its products.^[2,19]

Kedarnath NS and Abhilash PR conducted a study to evaluate the use of PRP in healing after impacted mandibular 3rd molar surgery and stated concluded that PRP contributed to better healing of soft tissues and bone and is a visible means of growth factor delivery.^[5] Alissa R et al., conducted an explorative randomized clinical trial to evaluate the influence of PRP on healing of extracted sockets. According to them PRP reduces the incidence of alveolar osteitis and improves soft tissue healing

whereas they were inconclusive regarding enhanced bone healing with use of PRP.^[20]

CONCLUSION

1. PRP contributes significantly to osteogenesis when mixed with bone graft
2. Healing is better with less post-operative swelling, pain when extracted sockets are supplemented with PRP
3. There is no incidence of allergic reaction with the use of allogeneic bone grafts

REFERENCES

1. Albanese A, Licata ME, Polizzi B, Campisi G. Platelet-rich plasma (PRP) in dental and oral surgery: from the wound healing to bone regeneration. *Immunity and ageing* 2013;10(23):1-10
2. Abdurrahman A. Al-Sammam, Khudhair A. Abd. The Role of Different Techniques to Enhance Periodontal Healing After Third Molar Surgery: A Review Article. *Biomedicine and Nursing* 2015;1(2):24-33
3. Toscano N, Holtzclaw D. Surgical Considerations in the Use of Platelet-Rich Plasma. www.compendiumlive.com 2008;29(3):182-185
4. Marx RE. Platelet-rich plasma: evidence to support its use. *J Oral Maxillofac Surg.* 2004;62:489-96
5. Marx RE. Platelet-rich plasma (PRP): what is PRP and what is not PRP? *Implant Dent.* 2001;10:225-8
6. Barona-Dorado C, Gonzalez-Regueiro I, Martin-Ares M, Arias-Irimia O, Jose-Maria, Martinez-Gonzalez. Efficacy of platelet-rich plasma applied to post-extraction retained lower third molar alveoli. A systematic review. *Med Oral Patol Oral Cir Bucal* 2014;19(2):e142-8
7. Simonpieri A, Del Corso M, Vervelle A, Jimbo R, Inchingolo F, Sammartino G, Dohan Ehrenfest DM, et al., Current knowledge and perspectives for the use of platelet-rich plasma (PRP) and platelet-rich fibrin (PRF) in oral and maxillofacial surgery part 2: Bone graft, implant and reconstructive surgery. *Curr Pharm Biotechnol* 2012;13(7):1231-56
8. Del Fabbro M, Bortolin M, Taschieri S. Is autologous platelet concentrate beneficial for post-extraction socket healing? A systematic review. *Int J Oral Maxillofac Surg* 2011;40:891-900
9. Sammartino G, Tia M, Marenzi G, di Lauro E, D'Agostino E, Paolo Claudio P. Use of Autologous Platelet-Rich Plasma (PRP) in Periodontal Defect Treatment After Extraction of Impacted Mandibular Third Molars. *J Oral Maxillofac Surg* 2005;63:766-70
10. de Obarrio JJ, Arauz-Dutari JJ, Chamberlain TM et al: The use of autologous growth factors in periodontal surgical therapy: Platelet gel biotechnology- Case reports. *Int J Periodontics Restorative Dent* 2000;20:486
11. Terranova VP, Martin GR: Molecular factors determining gingival tissue interaction with tooth structure. *J Periodont Res* 1982;17:530
12. Fonseca, Marciani, Turvey. *Platelet Rich Plasma and Bone Grafting. Oral and Maxillofacial Surgery.* Second Edition. 501-510
13. Gimeno FL et al., Preparation of platelet rich plasma as a tissue adhesive for experimental transplantation in rabbits. *Thromb J* 2006;4:18
14. Tsay RC et al., Differential growth factor retention by platelet rich plasma composites. *J Oral Maxillofac Surg* 2005;63:521-28

15. Gürbüz B, Pıkdöken L, Urhan M, Süer BT, Narin Y: Scintigraphic evaluation of early osteoblastic activity in extraction sockets treated with platelet-rich plasma. *J Oral Maxillofac Surg* 2008, 66:2454–2460.
16. Nanadkumar AS, Nandakumar K: Applications of platelet rich plasma for regenerative therapy in periodontics. *Trends Biomater Artif Organs* 2006;20(1):78-83
17. Ogundipe OK, Ugboko VI, Owotade FJ: Can autologous platelet-rich plasma gel enhance healing after surgical extraction of mandibular third molars? *J Oral Maxillofac Surg* 2011, 69:2305–2310.
18. Arenaz-Búa J, Luaces-Rey R, Sironvalle-Soliva S, Otero-Rico A, Charro-Huerga E, Patiño-Seijas B, García-Rozado A, Ferreras-Granados J, Vázquez-Mahía I, Lorenzo-Franco F, Martín-Sastre R, López-Cedrún JL: A comparative study of platelet-rich plasma, hydroxyapatite, demineralized bone matrix and autologous bone to promote bone regeneration after mandibular impacted third molar extraction. *Med Oral Patol Oral Cir Bucal* 2010, 15:483–489.
19. Moghe S, Saini N, Moghe A. Platelet-rich plasma in periodontal defect treatment after extraction of impacted mandibular third molars. *Natl J Maxillofac Surg* 2012;3(2):139-143
20. Alissa R, Esposito M, Horner K, Oliver R. The influence of platelet-rich plasma on the healing of extraction sockets: an explorative randomized clinical trial. *Eur J Oral Implantol* 2010;3(2):121-34

How to cite this article: Bokhari K, Nada A, Jawaher A, Falah H, Ismail A. Healing of Extracted Socket after Surgical Removal of Impacted Mandibular 3rd Molar: A Comparison of PRP VS PRP with Bone Graft. *Ann. Int. Med. Den. Res.* 2018; 4(5):DE36-DE41.

Source of Support: Nil, **Conflict of Interest:** None declared