

A Study of Characteristics Autopsy Findings in Hair Dye Poisoning.

C. Manoharan¹, R. Sudalaimuthu², A. Edwin Joe³, Heber Anandan⁴

¹Associate Professor of Forensic Medicine, Government Thoothukudi Medical College.

²Associate Professor of Forensic Medicine, Government Tirunelveli Medical College.

³Professor of Forensic Medicine / Dean, Government Thoothukudi Government Medical College.

⁴Clinical Epidemiologist, Dr.Agarwal's Healthcare Limited, Tamilnadu, India.

Received: December 2018

Accepted: December 2018

Copyright: © the author(s), publisher. Annals of International Medical and Dental Research (AIMDR) is an Official Publication of "Society for Health Care & Research Development". It is an open-access article distributed under the terms of the Creative Commons Attribution Non-Commercial License, which permits unrestricted non-commercial use, distribution, and reproduction in any medium, provided the original work is properly cited.

ABSTRACT

Background: Incidence of hair dye poisoning has been rising in many regions of the country due to easy availability. Mortality rates vary between 0.03% -60%. Post mortem findings in all the cases include laryngeal oedema, oedema of vocal cords and epiglottis. Cause of death in all the cases was probably asphyxia, multiorgan failure, and cardiac toxicity. **Aim:** To ascertain the cause of death in all the cases who died of hair dye poisoning. **Methods:** 24 patients who died of hair dye poisoning and who underwent an autopsy in Thoothukudi Government Medical College Hospital for the period from April 2009 to March 2010 were included in the study. **Results:** Facial puffiness, protruded tongue clinched in between the teeth, swollen neck, blood mixed froth oozing from the mouth, Bluish discoloration of extremities and conjunctival ecchymosis were seen in all the 24 patients. Histological examination of lung parenchyma showed infiltrated of lymphocytes and mononuclear cells, congestion in the pulmonary vasculature, mucosal and submucosal oedema in the laryngeal region along with infiltrates of mast cells, mononuclear cells, and lymphocytes. Pulmonary oedema and petechial haemorrhages on the myocardial surface were also noted. **Conclusion:** There are a high incidence and the rapid rise of hair dye poisoning in this area. All the autopsies in patients who died of hair dye poisoning showed severe cervicofacial oedema, bluish discoloration of extremities, conjunctival congestion and protruded tongue. All of them had evidence of asphyxia as the cause of death.

Keywords: Hair Dye, Poisoning.

INTRODUCTION

With hair dyes gaining in popularity as an easy method of poisoning, either by suicide or homicide, its incidence has been rising in many regions of the country.^[1-3] Oral ingestion of paraphenylenediamine (PPD) main toxic component of permanent hair dye, causes severe angioedema of the upper airway accompanied by a swollen, dry, hard and protruding tongue, and requires emergency airway management. PPD intoxication also results in multisystem involvement causing rhabdomyolysis and acute kidney injury (AKI), flaccid paralysis, severe gastrointestinal manifestations, cardiotoxicity, and arrhythmias.^[4,5] The time of presentation to the hospital is an important risk factor for developing oropharyngeal edema, which in turn determines the risk of mortality. Mortality rates vary between 0.03%-60%. Postmortem findings in all the cases include laryngeal oedema, oedema of vocal cords

and epiglottis. Cause of death in all the cases were probably asphyxia, multiorgan failure and cardiac toxicity.^[6,7]

Aim

To ascertain the cause of death in all the cases who died of hair dye poisoning.

MATERIALS AND METHODS

This prospective study was conducted in Department of Forensic Medicine, Thoothukudi Government Medical College.

All patients who died of hair dye poisoning in the hospital for the period from April 2009 to March 2010 were included in the study.

108 patients were treated for hair dye poisoning in the hospital during this period. Out of this, 24 patients died in spite of intensive treatment. An autopsy was conducted in all these patients.

Demographic data of hair dye poisoning fatalities like incidence, age, sex, marital status, manner of poisoning, fatal dose & fatal period of hair dye poison, histopathological findings, postmortem findings and chemical analysis reports were studied.

Name & Address of Corresponding Author

Dr. A. Edwin Joe,
Professor of Forensic Medicine / Dean,
Government Thoothukudi Medical College
Tamilnadu, India

RESULTS

In our 108 patients were included 38 male and 70 female. 24 were expired, 6 male and 18 female. [Figure 1] The age group ranged from 13-45 with a mean age of 24.7 ±6.51. Higher number of cases reported in 21 to 30 years age group. [Table 1] The mean amount of ingestion was 75-100ml. There is no apparent dose-toxicity relationship. Meantime of arrival to the hospital was ranging from 1 hours and 30 minutes to 10 hours with mean of 4 hours 03 minutes ±1.73. The autopsies of all the patients were done within 24 hours. Facial puffiness protruded tongue clinched in between the teeth, swollen neck, blood mixed froth oozing from the mouth, Bluish discoloration of extremities and conjunctival ecchymosis were seen in all the 24 patients. Laryngeal mucosal swelling, hyperaerated lungs are seen in all the deceased persons. All the internal organs showed characteristic greenish discoloration.

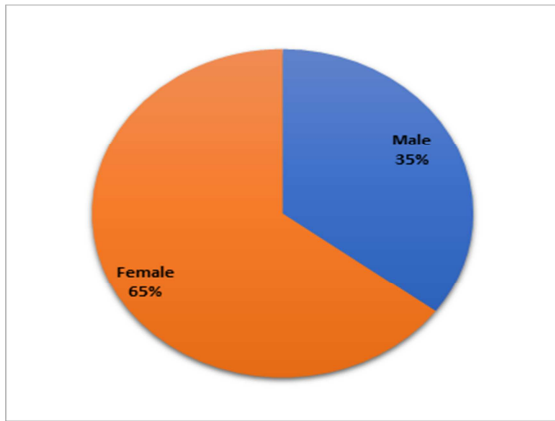


Figure 1: Gender distribution

Table 1: Distribution of age group

Age group	Patients	Expired	
		Male	Female
10-20	27 (25%)	2	2
21-30	58 (53.7%)	2	10
31-40	20 (18.5%)	1	4
41-55	3 (2.8%)	1	2
Total	108	6	18

The postmortem findings were observed during the autopsies conducted on the hair dye poisoning death cases. Among these findings Larynx and Trachea edema was most common 66.6%, followed, mucosa ulceration was in 12.5% cases, edema lungs, facial swelling, brown color hypostasis, protruded tongue were noted.

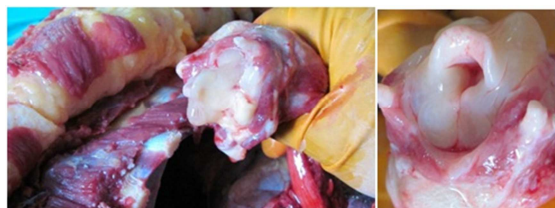

Figure 2: Picture of Glottis

Histological examination of lung parenchyma showed infiltrated of lymphocytes and mononuclear cells, congestion in the pulmonary vasculature, mucosal and submucosal oedema in the laryngeal region along with infiltrates of mast cells, mononuclear cells, and lymphocytes. Pulmonary oedema and petechial haemorrhages on the myocardial surface were also noted.

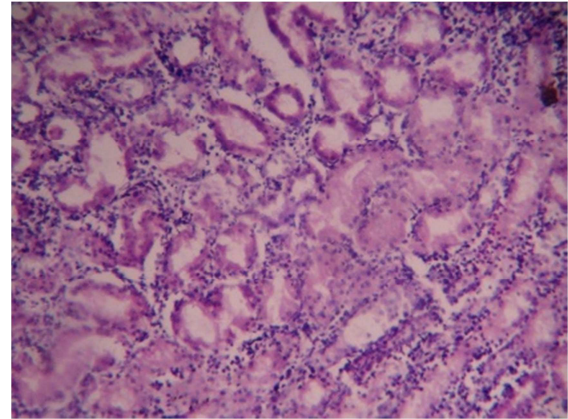


Figure 3: Inflammatory Exudate

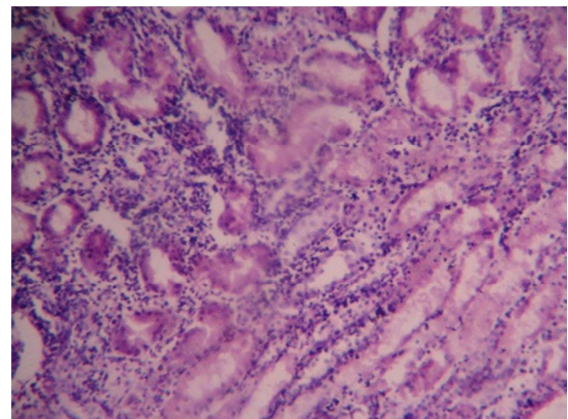


Figure 4: Congestion In Lungs

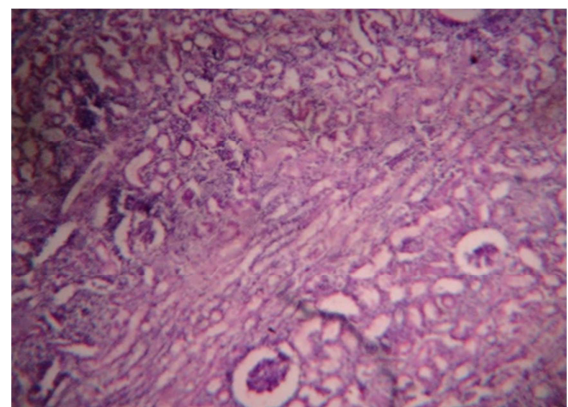


Figure 5: Acute Tubular Necrosis

DISCUSSION

Paraphenylenediamine is a coal tar (Paranitraniline) derivative which, on oxidation produces Bondrowski's base, which is allergenic, mutagenic

and highly toxic.^[2,4] Nott first documented paraphenylenediamine poisoning in an owner of a hair salon in 1924.^[3,8] Paraphenylenediamine causes severe angioneurotic edema, muscular edema, shock, rhabdomyolysis and intravascular haemolysis with haemoglobinuria (chocolate colored urine) culminating in acute renal failure,^[2,9] cardiotoxicity resulting in myocarditis and fatal arrhythmias causing sudden death.^[2,10,11] Apart from respiratory, renal, neurological, haematological and cardiac manifestations were also noted.^[2,4,10] Respiratory syndrome following hair dye ingestion is represented by asphyxia and respiratory failure secondary to inflammatory oedema involving the cricopharynx and larynx.^[2] This compound can cause angioneurotic edema with respiratory distress.^[7,12] Swollen face with asphyxia was noted by Yagi et al.^[13] and Bourquia A et al.^[14] Face and neck swelling with respiratory distress and convulsions was noted in a study by Verma et al.^[10] Suliman et al. who studied 150 patients with Paraphenylenediamine poisoning found angioneurotic edema in 68%.^[4]

CONCLUSION

There are a high incidence and rapid rise of hair dye poisoning in this area. All the autopsies in patients who died of hair dye poisoning showed severe cervicofacial oedema, bluish discoloration of extremities, conjunctival congestion and protruded tongue. All of them had evidence of asphyxia as the cause of death. Myocarditis was also documented in some patients. So, reaching the hospital promptly and timely medical help has a major impact on mortality. Many patients also developed renal failure and cardiac arrhythmias. These alarming facts suggest the necessity to impose regulation on the free availability of hair dye. Proper toxicity warning on the hair dye labels, counseling adolescent girls to withstand stress, public education regarding the potential toxicities of these compounds is imperative to reduce the mortality.

REFERENCES

1. Eddeleston M. Patterns and problems of deliberate self-poisoning in the developing world. *QJm* 2000; 93: 715-31.
2. Krishnaswamy Sampathkumar, Sooraj Yesudas. Hair dye poisoning and the developing world. *J Emerg Trauma Shock*. 2009 May-April; 2 (2): 129-131.
3. Filali A, Semlali I, Ottaviano V, Furani C, Corradini D, Soulayamani R, A retrospective study of acute systemic poisoning of Paraphenylene diamine (occidental takawt in Morocco). *Afr J Tradit Complement Altern Med* 2006;3(1):142-9 (medline)
4. Suliman SM, Fadlalla M, Nasr Mel M, et al. Poisoning with hair dye containing paraphenylene diamine: Ten years experience. *Saudi J Kidney Dis Transpl* 1995; 6: 286-9 (medline)
5. Kallel H, Chelly H, Dammak H, Bahloul M, Ksibi H, Hamida Cb et al. Clinical manifestations of systemic paraphenylene

- diamine intoxication. *J Nephrol*. 2005 May-Jun; 18(3): 308-11 (medline).
6. Singla S, Miglani S, Lal AK, Gupta P, Agarwal AK. Paraphenylene diamine poisoning. *J Acad clin care Med* 2005; 6: 236-8.
7. Bhargava P, Matthew P. Hairdye poisoning. *J Assoc physicians India* 2007; 55: 871-2 (Medline)
8. Nott HW. Systemic poisoning by hair dye. *The Br Med J* 1924; 1: 421-2.
9. Chugh KS, Malik GH, Singhal PC. Acute renal failure following paraphenylenediamine (hair dye) poisoning. Report of 2 cases. *J. Med* 1982; 13:131-137.
10. Verma R, Tewari N, Jaiswal S, Rastogi V, Saigh DK, Tiwari A. Fatal poisoning caused by oral ingestion of a hair dye. *The Internet J of emergency and Intensive Care medicine* 2008;11:1.
11. Soni SS, Nagarik AP, Dinaker M, Adikey GK, Raman A. Systemic toxicity of paraphenylene diamine. *Indian J med Sci* 2009; 63: 164-6. (medline)
12. Sir Hashim M, Hamza YO, Yahia B, Khogali FM, Sulieman GI. Poisoning from henna dye and paraphenylene diamine mixture in children in Khartoum. *Ann. Tro. Paediatr*. 1992; 12(1): 3-6.
13. Yagi H, el Hind AM, Khalil SI. Acute poisoning from hair dye. *East Afr Med J*. 1991 68(6); 404-11.
14. Bourquia A, Jabrane AJ, Ramdani B, Zaid D. Toxicitesystemique de la paraphenylene diamine, Quatre observations. [Article in French]. *Presse med*. 1998; Oct 15; 17(35); 1798-800.

How to cite this article: Manoharan C, Sudalaimuthu R, Joe AE, Anandan H. A Study of Characteristics Autopsy Findings in Hair Dye Poisoning. *Ann. Int. Med. Den. Res.* 2019; 5(1):FM01-FM03.

Source of Support: Nil, **Conflict of Interest:** None declared