

# Clinico-Histopathological Study of Ovarian Neoplasms in a Tertiary Care Center.

Harshita Vaibhav<sup>1</sup>, E. Girikumar<sup>2</sup>, Dilip Hari Mandke<sup>3</sup>, Ravi Nandan Prasad Sinha<sup>4</sup>

<sup>1</sup>Assistant Professor, Department of Pathology, Great Eastern Medical School & Hospital, Srikakulam, Andhra Pradesh.

<sup>2</sup>Professor & Head, Department of Pathology, Great Eastern Medical School & Hospital, Srikakulam, Andhra Pradesh.

<sup>3</sup>Professor, Department of Pathology, Great Eastern Medical School & Hospital, Srikakulam, Andhra Pradesh.

<sup>4</sup>Professor, Department of Pathology, Darbhanga Medical College, Darbhanga, Bihar.

Received: January 2019

Accepted: January 2019

**Copyright:** © the author(s), publisher. Annals of International Medical and Dental Research (AIMDR) is an Official Publication of "Society for Health Care & Research Development". It is an open-access article distributed under the terms of the Creative Commons Attribution Non-Commercial License, which permits unrestricted non-commercial use, distribution, and reproduction in any medium, provided the original work is properly cited.

## ABSTRACT

**Background:** Ovarian tumours are common and account for 80% of all ovarian neoplasms. An accurate and early diagnosis of lesions is helpful in proper diagnosis and management of these cases. **Methods:** The present observational study was conducted upon 84 ovarian masses from 68 patients. Background details of the patients, clinical features and operative findings were noted from the case history sheets. Findings of histopathological examination were noted. **Results:** Most of the patients were above 40 years of age. 95.2% neoplasms were benign in nature. 1.2% was borderline and 3.6% malignant. Surface epithelial tumours contributed to 70.2%, germ cell tumours 25% and sex cord stromal tumours 4.8%. **Conclusion:** Benign ovarian tumours are more common than malignant ones. Of the benign ones, epithelial tumours are commonest.

**Keywords:** Histopathology, Ovarian lesions.

## INTRODUCTION

Ovarian cancer is the most common cause of death due to malignancy of female genital tract and constitutes 25% of all these tumours.<sup>[1]</sup> Ovarian tumours are common and account for 80% of all ovarian neoplasms.<sup>[2]</sup> It has been found that majority of the ovarian lesions are functional and do not need major treatment. Surgery may be needed for large, persistent and painful cystic lesions.<sup>[3]</sup> Ovarian neoplasms are usually detected at a late stage when they become large, as they cause only mild symptoms.<sup>[4]</sup> An accurate and early diagnosis of lesions is helpful in proper diagnosis and management of these cases.

### Aims & objectives

The present study was conducted to find the histopathological find out the histopathological spectrum of benign and malignant ovarian neoplasms received in the department of Pathology.

### Name & Address of Corresponding Author

Dr. Harshita Vaibhav,  
Assistant Professor,  
Department of Pathology,  
Great Eastern Medical School & Hospital,  
Aditya Educational Society,  
Ragolu Village,  
Srikakulam,  
Andhra Pradesh,  
PIN-532484.

## MATERIALS AND METHODS

The present study was observational in nature conducted at the Department of Pathology, Great Eastern Medical School & Hospital, Srikakulam, Andhra Pradesh. The study material consisted of a total of 84 ovarian masses from 68 patients from either/ both sides received in the department for examination. The patients admitted in the hospital for surgery of ovarian masses were included. Those patients who were managed conservatively were excluded.

Background details of the patients, clinical features and operative findings were noted from the case history sheets. Biopsies were received in the department and fixed in 10% formalin. Gross examination of the mass was done and salient features were recorded. Multiple sections were taken from the surgical specimens, sections were stained with conventional Haematoxylin and Eosin (H&E) stain and subjected for microscopic examination. The ovarian pathology was classified in accordance with the WHO classification

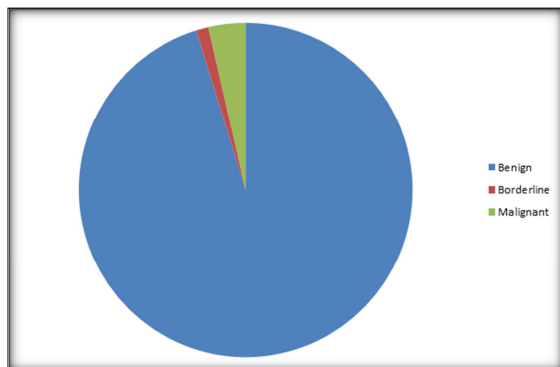
Data was recorded in pretested proforma. It was entered in Microsoft Excel and analyzed using SPSS v 16.0. Variables were presented as frequency & percentage of Mean & SD as appropriate. Tests of significance were done and p-value of less than 0.05 was considered to be statistically significant.

**RESULTS**

A total of 84 ovarian masses were studied. [Table 1] shows the age of the patients. It was seen that most of the patients were above 40 years of age.

**Table 1: Age of the study subjects**

Age group (Years)	Frequency (n=84)	%	95% CI
<19	8	9.5	5.4-13.6 %
20-39	19	22.6	16.8-28.4 %
40-59	47	56	49.1-62.9 %
>59	10	11.9	7.4-16.4 %
<19	8	9.5	5.4-13.6 %



**Figure 1: showing nature of ovarian tumours**

[Table 2] shows that 95.2% neoplasms were benign in nature. 1.2% was borderline and 3.6% malignant.

**Table 2: Nature of ovarian neoplasm**

Nature	Frequency (n=84)	%	95% CI
Benign	80	95.2	92.2-98.2 %
Borderline	1	1.2	0-2.7 %
Malignant	3	3.6	1-6.2 %

**Table 3: Histopathological findings**

Histopathology	Frequency (n=84)	%	95% CI
Surface epithelial tumours	59	70.2	63.8-76.6 %
Serous cyst adenoma	39	46.4	39.5-53.3 %
Serous cyst adenocarcinoma	1	1.2	0-2.7 %
Mucinous cyst adenoma	15	17.9	12.6-23.2 %
Mucinous cyst adenocarcinoma	2	2.4	0.3-4.5 %
Borderline mucinous cyst adenocarcinoma	1	1.2	0-2.7 %
Endometroid adenocarcinoma	1	1.2	0-2.7 %
Germ cell tumor	21	25	19-31 %
Benign cystic teratoma	20	23.8	17.9-29.7 %
Struma ovary	1	1.2	0-2.7 %
Sex cord stromal tumor	4	4.8	1.8-7.8 %
Fibroma	3	3.6	1-6.2 %
Granulosa cell tumor	1	1.2	0-2.7 %

[Table 3] shows the findings of histopathological examination. Surface epithelial tumours contributed to 70.2%, germ cell tumours 25% and sex cord

stromal tumours 4.8%. 46.4% specimen had serous cyst adenoma, 1.2% serous cyst adenocarcinoma, 17.9% mucinous cyst adenoma, 2.4% mucinous cyst adenocarcinoma and 1.2% each for borderline mucinous cyst adenocarcinoma and endometroid adenocarcinoma. 23.8% had benign cystic carcinoma and 1.2% had struma ovary.

**DISCUSSION**

The present study included 84 specimen of ovarian mass. It was observed that most of the patients were above 40 years of age. Dutta et al found that benign tumours were common in 21-30 years of age, borderline tumours in 61-70 years and malignant in 41-50 years of age group.<sup>[5]</sup> Chauhan et al observed that the youngest patient was 11 years whereas the oldest was 73 years in their study.<sup>[6]</sup> Wills et al found that maximum number of benign ovarian tumors was in the 21-40 year age group and a similar number in the 41-60 year age group. All the malignant tumors (100%) were in the 41-60 year age group.<sup>[7]</sup> Thakkar et al found that majority of the cases of malignant, benign & borderline lesions were seen in age group of 40-59 years.<sup>[8]</sup> Prakash et al observed that the age group of 20-39 years constituted the majority of patients (53.4%).<sup>[9]</sup>

Abdominal pain was the single most common presenting symptom followed by menorrhagia as also found by Thakkar et al. In non-neoplastic lesions menorrhagia was the commonest symptom.<sup>[8]</sup> In the present study, 95.2% neoplasms were benign in nature. 1.2% was borderline and 3.6% malignant. Surface epithelial tumours contributed to 70.2%, germ cell tumours 25% and sex cord stromal tumours 4.8%. 46.4% specimen had serous cyst adenoma, 1.2% serous cyst adenocarcinoma, 17.9% mucinous cyst adenoma, 2.4% mucinous cyst adenocarcinoma and 1.2% each for borderline mucinous cyst adenocarcinoma and endometroid adenocarcinoma. 23.8% had benign cystic carcinoma and 1.2% had struma ovary.

Dutta et al found that of the primary ovarian tumours (n=68), 52 were benign, 5 were borderline and 11 were malignant. Histopathologically, surface epithelial tumours were the commonest, second most common was germ cell tumour followed by sex cord stromal tumours.<sup>[5]</sup> Chauhan et al found that 34.3 % of the cases were in the non-neoplastic category and 56 % in the neoplastic category. Benign serous cystadenoma constituted for 32% of all ovarian neoplasm. Mucinous cystadenoma was the second most common tumor. In the nonneoplastic category, Corpus luteal cysts formed the largest group (45.7%); followed by follicular cysts (33.3%).<sup>[6]</sup>

Wills et al found that among the neoplastic lesions, 91.1% were benign, 7.1% were malignant and there was only 1.8% with borderline malignant histopathology. Serous cyst adenomas (44.6%), followed by Germ Cell tumors (23.2%) and

mucinous cyst adenoma (17.8%) were the most common benign tumors.<sup>[7]</sup> Thakkar et al reported that 84.5% tumours were benign, 2.3% were borderline and 13.2% were malignant tumors. The serous tumors formed the largest group (65.4 %) followed by germ cell tumors (17.8 %) which was followed by mucinous tumors which accounted to 8.5 % of the total found in their study.<sup>[8]</sup>

Hatwal et al found that 69.54% were non-neoplastic lesions and 30.46% were neoplastic lesions. Of the various neoplastic lesions, serous tumours were the most common neoplasm seen in 66% cases and were predominantly unilateral.<sup>[10]</sup>

**How to cite this article:** Vaibhaw H, Girikumar E, Mandke DH, Sinha RNP. Clinico-Histopathological Study of Ovarian Neoplasms in a Tertiary Care Center. *Ann. Int. Med. Den. Res.* 2019; 5(2):PT33-PT35.

**Source of Support:** Nil, **Conflict of Interest:** None declared

## CONCLUSION

It is concluded from the present study that benign ovarian tumours are more common than malignant ones. Of the benign ones, epithelial tumours are commonest. Early diagnosis is helpful in reducing morbidity and mortality among these patients.

## REFERENCES

1. Pradhan A, Sinha AK, Upreti D. Histopathological patterns of ovarian tumours at BPKIHS. *Health renaissance* 2012; 10: 87-97.
2. Azizs, Kuperstein G, Rosen B, Cole D, Nedelew R, McLaughlin J, Narod SA et al. A genetic epidemiologic study of carcinoma of the fallopian tube. *Gynecologic oncology* 2001; 80:341.
3. Holt VL, Cushing-Haugen KL, Daling JR. Risk of Functional Ovarian Cyst: Effects of Smoking and Marijuana Use according to Body Mass Index. *Am J Epidemiol* 2005;161:520-5.
4. Forae GD, Aligbe JU. A histopathological overview of ovarian lesions in Benin City, Nigeria: How common is the functional cyst? *Int J Med Public Health.* 2014;4:265-8.
5. Dutta A, Imran R, Saikia P, Borgohain M. Histopathological spectrum of ovarian neoplasms in a tertiary care hospital. *International Journal of Contemporary Medical Research* 2018;5(8):H1-H4.
6. Chauhan J, Alva SP, Rajesh G. Histomorphological Stratification of Ovarian Pathology. *Indian Journal of Applied Research* 2018;8(8): 73-5.
7. Wills V, Mathew R. A study on clinico-histopathological patterns of ovarian tumors. *Int J Reprod Contracept Obstet Gynecol* 2016;5:2666-71.
8. Thakkar NN, Shah SN. Histopathological Study of Ovarian Lesions. *International Journal of Science and Research (IJSR)* 2015; 4(10):1745-9.
9. Prakash A, Chinthakindi S, Duraiswami R, Indira.V. Histopathological study of ovarian lesions in a tertiary care center in Hyderabad, India-a retrospective five-year study. *Int J Adv Med* 2017;4:745-9.
10. Hatwal D, Choudhari S, Batra N, Bhatt P, Bhatt S. Clinico-histopathological analysis of neoplastic and non-neoplastic lesion of ovary in Garhwal region of Uttarakhand: A 4 year study at tertiary level hospital. *Indian Journal of Pathology and Oncology*, April-June 2016;3(2);133-140.