

Characteristics of Morphometric Parameters of the Maxillo-Facial Region of Patients with Gnathic Forms of Occlusion Abnormalities

Dilshod M. Dusmukhamedov¹, Saidmurodxon S. Murtazayev¹, Abduazim A. Yuldashev¹, Dilnavoz K. Dusmukhamedova²

¹Associate professor, Tashkent State Dental institute, Tashkent, Uzbekistan.

²Assistant of teacher, Tashkent State Dental institute, Tashkent, Uzbekistan.

Received: July 2019

Accepted: July 2019

Copyright: © the author(s), publisher. Annals of International Medical and Dental Research (AIMDR) is an Official Publication of “Society for Health Care & Research Development”. It is an open-access article distributed under the terms of the Creative Commons Attribution Non-Commercial License, which permits unrestricted non-commercial use, distribution, and reproduction in any medium, provided the original work is properly cited.

ABSTRACT

Background: The problems of diagnosis and therapy of patients with various deformities of the facial skeleton are widely covered. The aim of the research is to characterize the morphometric parameters of the maxillofacial region in patients with gnathic forms of occlusion abnormalities (GFOA). **Methods:** The data from the archives of the 38 patients (ethnic Uzbeks) with the gnathic forms of occlusion anomalies, who have a treatment at the Clinic of Tashkent State Dental Institute, was analyzed. In addition, the criteria of normal range for the ethnic Uzbeks were determined by the cephalometric evaluation during the treatment of the patients with the dent maxillofacial anomalies. **Results:** The data obtained served as the basis for the judgment about the deviations of the norm in the facial skeleton and, in particular, in its gnathic Department among ethnic Uzbeks. These parameters will be the norm criteria in cephalometric studies in the treatment of patients with dentoalveolar anomalies, in particular patients with GFAO, which ultimately facilitates the clinical diagnosis, the preparation of a rational plan of orthodontic, surgical treatment and evaluation of their immediate and long-term results. **Conclusion:** Thus, the data obtained by us confirm the idea that cephalometric analyses are often based on comparison of the data obtained as a result of examination of a particular patient (group of patients) with the average values in this population.

Keywords: Orthognathic surgery, deformities of jaws, morphometric analysis.

1

INTRODUCTION

The analysis of the data of clinical studies of domestic and foreign authors shows that the search for the best algorithm for the treatment of patients with congenital and acquired deformities of the facial skeleton has been going on for more than 40 years and does not lose its relevance to present day (Drobyshev A.Yu., 2007; Gunko V.I., 2009; Nabiev F.Kh., 2009; Senyuk A.N. 2010; Syomkin VA, 2011; Posnick J.C., 2008; Costa F., Politi M., 2008). The importance of this problem is primarily determined by the high frequency of this pathology (Shamsudinov A.Kh., 2001; Balin V.N., 2007; Medvedev Yu.A., 2009, Khurramova Sh et al., 2016).

Nowadays, the issues of diagnosis and treatment of patients with various deformities of the facial skeleton are widely covered. However, the issues of aesthetic rehabilitation of this category of patients

remain open. These patients undergo orthognathic and reconstructive surgery, orthodontic treatment, cosmetic interventions, but little attention is paid to the accompanying functional and aesthetic changes in the surrounding structures (Pshenysnov K.P. et al., 2004; Pavlyuchenko L.L. 2005; Oganessian S.S., 2008; Higuera S. et al., 2007; Becker D.G., Bloom J., 2008; Kantas I., et al., 2008, Abdullaev B. et al., 2017).

Purpose of research

To characterize the morphometric parameters of the maxillofacial region in patients with gnathic forms of occlusion abnormalities (GFOA).

MATERIALS & METHODS

To assess the morphometric parameters of the maxillofacial region of patients with GFOA, an analysis of archival material was carried out in 38 patients-ethnic Uzbeks who were on dispensary observation in the Department of pediatric maxillofacial surgery of the hospital of Tashkent State Dental Institute. To identify deformities of the facial skeleton depending on the severity in one or another plane, a typical accessory, we used the

Name & Address of Corresponding Author

Dr. Dilshod M. Dusmukhamedov.
Associate professor,
Tashkent State Dental institute,
Tashkent,
Uzbekistan.

classification of malocclusion proposed by E. Engle (1898).

Depending on the type of malocclusion patients after diagnosis, were divided into the following 2 groups: 1 group comprised of the class II patient (E. Engel, 1898) distal occlusion (upper macro prognathia, lower micro retrognathia); 2 – group - class III – class III occlusion (lower macro prognathia, top micro retrognathia). All patients underwent clinical and x-ray examination: clinical examination, detection of complaints, assessment of the state of the dental-jaw system and tissues of the maxillofacial area, anthropometry of facial proportions, telereöntogenography in direct and lateral projections.

Table 1: Distribution of patients according to age and sex

Group	Sex	Age groups (years)			In total	
		14-19	20-24	25-35		
1 группа	Male	4	2	1	7	16
	Female	5	4	-	9	
2- группа	Male	3	6	-	9	22
	Female	7	4	2	13	
Total		19	16	3	38	

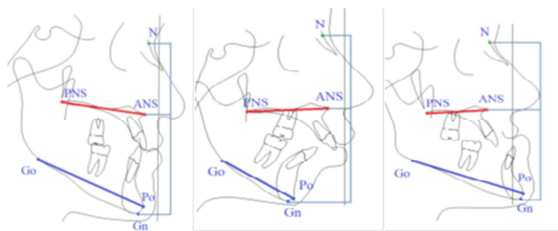


Figure 1: Schematic representation of the length of the facial skeleton:

PNS-ANS –absolute length of the upper jaw,

Go-Pg –the absolute length of the mandible,

N-ANS-height of the middle third of the face,

ANS-Gn is the height of the lower third of the face.

A-the size of the facial skeleton in patients with orthognathic bite,

B-the size of the facial skeleton in patients with distal occlusion,

C dimensions of the facial skeleton in patients with mesial occlusion

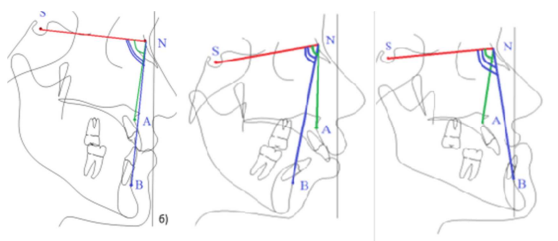


Figure 2: Schematic representation of angles: SNA, SNB, ANB:

A-with orthognathic bite,

B-with distal occlusion,

C-with a mesial bite.

To assess the skeletal signs of jaw development, symmetry of facial skull bones, the main

cephalometric parameters, we used cephalometric indicators of the computer program Dolphin and studied the following indicators - the absolute length of the upper jaw (PNS-ANS), the absolute length of the lower jaw (Go –Pg), the height of the middle third of the face (N-ANS), the height of the lower third of the face (ANS-Gn) and the position of the upper and lower jaw and interdental differential (SNA, SNB, ANB) [Figure 2]. As control indicators of cephalometry of norm of persons of the Uzbek population (S. S. Murtazayev, 2017) are taken. [Figure 1]

In our opinion, these examinations allow us to make a comparative assessment of skeletal signs of jaw development, to assess the symmetry of the bones of the facial skull, to assess the main cephalometric parameters of the patient with GFOA.

RESULTS & DISCUSSION

Analysis of the results of the study of aesthetic parameters before surgery in patients of group 1 shows that the ratio of the average height of the face is more than 1 in relation to the lower height (normally 1:1), which indicates an increase in the size of the upper jaw or a decrease in the size of the lower jaw.

In this study group, 14 patients presented aesthetic complaints (87.5%), which were expressed in a decrease in the lower third of the face and the crowding of the dentition in 11 patients (68.8%), insufficient visualization of the incisors of the upper jaw with a smile in 5 patients (31.3%). Patients of this group are characterized by complaints of clicking in the area of temporomandibular joints-3 patients (18.7%), fatigue of masticatory muscles in 4 patients (25%) and difficulty of nasal breathing in 6 patients (37.5%).

In patients of this group, the characteristic features of the face were revealed: there was a violation of the proportions of the face due to the shortening of its lower part. Lobopodia crease located high and deep. All patients were characterized by a distal position of the chin relative to the middle part of the face. With a pronounced retroposition of the lower jaw in the resting position, the closing of the lips was disturbed: the mouth is half-open, from under the upper lip the incisors of the upper jaw are visible. The examination of the oral cavity in 1 patient (6.25%) revealed a small vestibule of the oral cavity in the anterior part of the lower jaw and a high attachment of the lower lip frenulum and oral mucosa strands. 2 patients (12.5%) had protrusion of incisors of both jaws, 3 patients (18.8%) - retrusion of the upper incisors, while all patients had a close position of the front teeth. In addition, all patients noted a deformity of the occlusal plane, distal occlusion of posterior teeth, the cartridge disocclusion (sagittal slot reached an average of 7 to 13 mm). The majority of patients had deep incisor

disocclusion, and 2 patients (12.5%) had vertical incisor disocclusion. There was also a deformation of the dental arches of the jaws: shortening of the lower dental arch, narrowing of the dental arches in the lateral parts.

The results of the study of aesthetic parameters before surgery in patients of group 2 show the presence of a variety of skeletal disorders. In patients of this group, the ratio of the average height of the face is less than 1 in relation to the lower height, which indicates an increase in the size of the lower jaw or a decrease in the size of the upper jaw.

In this group, all 22 patients complained of cosmetic defects (100%), which were expressed in excessive intensity of the chin Department – 21 cases (94.5%), and lengthening of the lower third of the face – 18 cases (81%). In addition, 4 patients (18%) complained of insufficient expression of gonial angles, the crowded position of the teeth worried 12 patients (54%), the tension in the closing of the lips and the presence of a "gingival" smile was observed in 13 patients (58.5%). Also, patients complained of "hump" in the back of the nose 7 (31.5%) and difficulty in nasal breathing 14 (63%), 9 patients (40.5%) noted the presence of difficulties in biting off food.

In patients of this study group was dominated by an increase in body length, which was combined with

an increase in gonial angle over 123-124°. The height of the chin of the lower jaw was increased. The height of the branches was within normal limits. In such patients, there was a decrease in the volume of the oral cavity and the wrong position of the tongue. The disproportion of anterior and posterior facial height is revealed. It should be noted that in patients with a pronounced increase in the gonial angle, the height of the lower jaw and the anterior facial height, "long face syndrome" was revealed and an increase in the inclination of the front teeth and vertical disocclusion of the dentition with a reverse overlap was observed.

Analysis of the results of the study of cephalometric parameters in patients of group 1 shows (tab.2) what the average length of the maxilla (PNS-ANS) in patients of this group was 50.5±0.31 mm, mean value of the absolute length of the mandible (Go-Gn) amounted to 74.5±1.21 mm, which indicates the small size of the lower jaw, the front elevation of the middle third of the face (N-ANS) amounted to 52.45±1.83 mm. The average value of the height of the lower third of the face (ANS-Gn) amounted to 61.1±1.88 mm, indicating that the underdevelopment of the lower third of the face.

Table 2: Linear cephalometric parameters of patients with GFOA, M+m (mm)

Research group	Sex	ANS-PNS (mm)	Go-me (mm)	Go-Gn (mm)	N-ANS (mm)	ANS-Gn (mm)	Ar-Go (mm)
1st Gr	M	52,0±0,51	71,6±0,64	75,9±0,83	53,1±0,72	63,3±0,47	54,7±1,27
	F	49,1±0,3	68,7±0,17	73,1±0,53	51,8±0,97	58,9±0,81	48,9±0,94
	Average	50,5±0,31	70,1±0,39	74,5±1,21	52,45±1,83	61,1±1,88	51,8±0,78
2nd Gr	M	50,1±0,72	75,8±1,14	82,6±0,92	52,2±0,24	72,5±0,19	59,3±0,61
	F	46,9±0,51	71,3±0,62	76,7±0,88	50,1±0,78	65,7±0,37	52,1±0,48
	Average	48,5±0,59	73,5±0,58	79,6±0,63	51,1±1,36	69,1±1,09	55,7±0,14
Control	M	51,9±0,52	73,9±0,82	79,7±0,82	54,93±0,58	68±0,84	54,9±0,74
	F	47,8±0,44	68,5±0,65	74,0±0,69	50,02±0,81	61,5±1,12	48,5±0,56
	Average	49,8±0,4	71,2±0,59	76,8±0,61	52,62±0,5	64,98±0,77	51,7±0,57

Note: the control group is study of S. S. Murtazayeva (2018).

In patients of 2nd group, the results of the study of cephalometric parameters show that the average length of the upper jaw (PNS-ANS) was 48.5±0.59 mm, indicating a small size of the upper jaw (tab.2). The average length of the mandible (Go-Gn) was 79.6±0.63 mm, indicating an increase in the size of the mandible. The mean height of the middle third of the face (N-ANS) was 51.1±1.36 mm, indicating a

small size of the middle third of the face. The average height of the lower third of the face (ANS-Gn) was 69.1±1.09 mm, indicating an increase in the size of the lower third of the face. The spread of indicators in the study group was very significant (the maximum size of the lower third varies from the maximum -76.3 mm to the minimum -57mm). This indicates a large variability of the original data.

Table 3: Angular cephalometric parameters of patients with GFOA, M+m (degrees)

Research	Sex	SNA angle (°)	SNB angle (°)	ANB angle (°)
1st Gr	M	84,1±0,83	77,8±1,19	8,1±0,33
	F	82,9±0,79	76,9±0,85	6,2±0,73
	Average	83,5±2,49	77,3±2,38	7,15±0,66
2nd Gr	M	81,4±0,27	87,9±0,54	-6,2±0,42
	F	80,2±0,65	85,1±0,81	-5,4±0,78
	Average	80,8±0,71	86,5±1,01	-5,8±0,64
Control	M	82,9±0,53	80,3±0,53	2,7±0,28
	F	82,1±0,44	79,6±0,44	2,6±0,23
	Average	82,5±0,35	79,9±0,34	2,7±0,18

Note: the control group is study of S. S. Murtazayeva (2018).

The results of studies of jaw angles in patients of group 1 show that the average value of SNA was $83.5 \pm 2.49^\circ$ [Table 3], which indicates a tendency to the anterior position of the upper jaw. The average value of the SNB angle was $77.3 \pm 2.38^\circ$, which indicates a decrease in the angle due to the small size of the lower jaw. The average value of the ANB angle index in patients with distal occlusion was $7.15 \pm 0.66^\circ$, which indicates an increase in the angle value.

In patients of 2nd group SNA angle had an average of $81.47^\circ \pm 0.71^\circ$ [Table 3], indicating the normal position of the upper jaw, the average angle SNB was $86.5 \pm 1.01^\circ$, indicating an increase in the angle and the size of the lower jaw. The average ANB angle representing the difference between SNA and SNB angles was $-5.8 \pm 0.64^\circ$.

CONCLUSION

Thus, the data obtained by us confirm the idea that cephalometric analyses are often based on comparison of the data obtained as a result of examination of a particular patient (group of patients) with the average values in this population. The data obtained will serve as the basis for the judgment about the deviations of the norm in the facial skeleton and, in particular, in its gnathic Department among ethnic Uzbeks. These parameters will be the norm criteria in cephalometric studies in the treatment of patients with dentoalveolar anomalies, in particular patients with GFAO, which ultimately facilitates the clinical diagnosis, the preparation of a rational plan of orthodontic, surgical treatment and evaluation of their immediate and long-term results.

REFERENCES

1. An algorithm for the treatment of patients with micrognathia the upper jaw and the lower jaw macrognathia / A. Kozlov, A. Yu. Drobyshev, I. A. Clip etc.// Dentistry for all.- 2013.- №1.- P. 12-19
2. Arutyunov S. D., persin L. S., Petrosyan D. E., Arutyunov S. D. Correlation rentgenologicheskii parameters of gnathicheskii part of the skull with anthropometric indicators of dentition and functional data research Dentistry. - 2001. - №5. - P. 40-46.
3. Baidik O. D. Morphological criteria for evaluation of orthognathic bite in representatives of different ethnic groups: Dis. of Candidate medical Sciences'. - Barnaul, 2005. - 137 p.
4. Bessonov, S. N. The role of orthognathic surgery in the formation of facial aesthetics // Aesthetic medicine. - 2012.- № 3.-P. 395-400.
5. Gordina G. S., Serova N. S... Glushko and others possibilities of computer tomography in patients with anomalies of the dentoalveolar system before surgical treatment // Bulletin of radiology. - 2016.- №3. - P. 143-148.
6. Manashev G. G. Variability of dental system depending on gender and Constitution: Dissertation of medical sciences'. - Krasnoyarsk, 2000. - 135 p.
7. Muzurova L. V. Morphometric characteristics of the angular parameters of gnathicheskii part of the skull and their

- correlation relationships among children of 13-16 years with a neutral occlusion // Actual problems of morphology: Sat. scientific. Tr. - Krasnoyarsk, 2006. - №5. - P. 115-117.
8. Nabiyev, F. H., Kotov, I. I., Libin, P. V., Dobrodeev, A. S., Ovsyannikov, A. G. Clinic, diagnosis and treatment of patients with dentoalveolar anomalies of the class II classification of Engle, accompanied by the obstructive sleep apnea syndrome // Annals of plastic, reconstructive and aesthetic surgery.-2017.- №2.- P. 19-29.
 9. Persin, L. S. Cephalometric substantiation of orthodontic diagnosis./ HP Persin, J. A., Lindenholtz, E. A. Cardboard, Z. I. Vagapov // . - 2010.
 10. Polma, L. V. diagnosis of aesthetic disorders and planning of complex rehabilitation of patients with sagittal occlusion abnormalities.: - Dis. ... Doc. honey, science. - Moscow-2009. - P. 211.
 11. Slabkovskaya A. B. transversally Diagnosis of abnormalities of occlusion according to the teleroentgenography // Orthodontics. - 2003. - №3. - P. 17-21.
 12. Trezubov V. N., Fadeev R. A. Planning and forecasting of treatment of patients with dental anomalies. - M: Medpress-INF 2005. - 224 p.
 13. Tsarik, V. S. Morphometric changes of maxillofacial parameters in complex (orthodontic and surgical) treatment of patients with mesial occlusion: Dis. ... kand. honey, science. - Moscow. - 2008. - P. 160.
 14. Abdullaev B., Giyazitdinova E., Musaeva Y. The Degree of Cognitive Impairment in Patients with Lacunar Stroke Depending on the Hemispheric Lateralization of the Lesion // American Journal of Psychiatry and Neuroscience. - 2017. - T. 5. - № 5. - C. 56.
 - Shokirov sh. T. Surgical treatment of secondary deformities of the upper jaw in congenital cleft lip and palate: Dis. ...Dr. med. Sciences: 14.00.21: - Tashkent, 2011. - 250 p.
 15. Yatskevich, O. S., Ivanov S. Yu., Muraev A. A. Distal occlusion: some aspects of diagnosis and complex orthodontic-surgical treatment / M. E. Zorich, O. S. Jackiewicz, S. Ivanov, A. A. Moore // Dental - 2014.- № 2. - P. 52-54.
 16. Abdullah M. Aldrees Lateral cephalometric norms for Saudi adults: a meta-analysis // The Saudi Dental Journal. - 2011. - Vol. 23. - P. 3-7
 17. Yan Dong et al. Three-Dimensional Anthropometric Analysis of Chinese Faces and Its Application in Evaluating Facial Deformity// J Oral Maxillofac Surg.- 2011 Vol.69(4).-P.195-206.
 18. Shokhsanam Khurramova & Bekhzod Abdullaev, 2017. "Development of Periodontitis after Antihelicobacter Therapy in Patients with Ulcer Disease," Journal of Diseases, Conscientia Beam, vol. 4(1), pages 1-7.

How to cite this article: Dusmukhamedov DM, Murtazayev SS, Yuldashev AA, Dusmukhamedova DK. Characteristics of Morphometric Parameters of the Maxillo-Facial Region of Patients with Gnathic Forms of Occlusion Abnormalities. Ann. Int. Med. Den. Res. 2019; 5(5):DE58-DE61.

Source of Support: Nil, **Conflict of Interest:** None declared