Original Article ISSN (O):2395-2822; ISSN (P):2395-2814

Retzius Space: Not A Single Anatomical Entity: New Insights, Simplified & Illustrated in A Laparoscopic Study during TEPP Hernioplasty for Inguinal Hernia.

Maulana Mohammed Ansari[1]

[1]Ex-Professor of General Surgery, Department of Surgery, J. N. Medical College, Aligarh Muslim University, Aligarh, UP, India.

Received: December 2017
Accepted: December 2017

ABSTRACT

Background: Casual internet surfing at times proves extremely rewarding with astonishing results. Chance finding of an unknown old PhD thesis prompted documentation of detailed description of retropubic spaces supplementary to the author's recent publication (Ansari MM. Ann Int Med Den Res 2017; 3(5): SG25-31.). **Methods:** Prospective study in adult patients with inguinal hernia who underwent laparoscopic total extra-peritoneal preperitoneal (TEPP) hernioplasty through standard 3-midline-port technique at J. N. Medical College, Aligarh between 2010 and 2015. **Results:** Under excellent fibre-optic light and magnified view during preperitoneal laparoscopy, multiple potential retropubic spaces were observed in the retropubic region, ranging from 4 to 7 in number. A total of four fissile potential retropubic spaces were recognized in 46 cases of TEPP hernioplasty when the posterior rectus sheath was incomplete (single- or double-layered) and the preperitoneal fascia as well as transversalis fascia was single-layered; a total of five fissile potential retropubic spaces were observed when preperitoneal fascia was double-layered along with presence of a single- or double-layered incomplete posterior rectus sheath (N=8); a total of five fissile potential retropubic spaces was also observed when the preperitoneal fascia was single-layered and the posterior rectus sheath was found single-layered but complete extending upto the pubic bone (N=10); a total of six fissile potential retropubic spaces were observed when the preperitoneal fascia was double-layered along with the presence of a single-layered complete posterior rectus sheath (N=3); and a maximum of seven fissile potential retropubic spaces was recognized, given the presence of a double-layered complete posterior rectus sheath and a double-layered preperitoneal fascia at the same time (N=1). **Conclusion:** Instead of a single Retzius space, multiple loosely fissile potential interfascial spaces (4-7) were documented in retropubic region, necessitating re-evaluation of Retzius space anatomy, in order to help TEPP hernia surgeon to execute the procedure with ease, rapidity and safety.

Keywords: Retzius space, retropubic spaces, TEPP anatomy, preperitoneal anatomy, Rectusial fascia, Transversalis fascia, preperitoneal fascia, complete posterior rectus sheath.

"One might think that the science of anatomy has completed the detailed description of the human body ... However, some structures are still problems..." --- Baumann (1942)[1]

INTRODUCTION

In 1858, a Swedish anatomist Anders Adolf Retzius described a retropubic space bounded by transversalis fascia, which was named after him.[2] However, the boundaries of the Retzius space have been a matter of conflicting descriptions.[3] In a classical study of cadaveric anatomy in 1948, Mark Allan Hayes suggested for the first time that Retzius space is not a single anatomic entity but consists of multiple fascial spaces secondary to presence of several fasciae and interfascial clefts in the retropubic region, necessitating re-evaluation of the retropubic anatomy in general and anatomy of the Retzius space in particular.[3] Somehow, Hayes' thesis remained largely unknown to the anatomists and surgeons alike, and I also happened to come across by chance during general internet surfing soon after publishing our live observations of the Retropubic and Bogros spaces made during the laparoscopic total extraperitoneal preperitoneal (TEPP) hernioplasty for the inguinal hernia.[4] Therefore, live surgical anatomy of the retropubic spaces is herein presented in more details with simplified illustrations and new perspectives.

Name & Address of Corresponding Author
Dr. Maulana Mohammed Ansari
Ex-Professor of General Surgery,
Department of Surgery,
J. N. Medical College,
Aligarh Muslim University, Aligarh, UP, India.

MATERIALS AND METHODS

Elective 68 TEPP hernioplasties (52 Unilateral and 8 Bilateral) were successfully performed in 60 adult male patients with primary inguinal hernia at the J. N. Medical College and Hospital, AMU, Aligarh, under the patient's informed consent and

Institutional ethics committee approval. Main exclusion criteria included patients' age < 18 years, previous lower abdominal surgery, complicated/ recurrent inguinal hernia, femoral hernia, and unfit for general anaesthesia. Surgical technique of 3-midline ports was consistently same as reported by the author previously.[4-12] Telescopic dissection with unhurried gentle to-and-fro movements of the 0º 10-mm telescope was initially utilised for creating space in the posterior rectus canal and retropubic region under low pressure setting (12 mmHg) of CO2 insufflation, followed later by blunt/sharp instrument dissection for definitive creation of adequate preperitoneal space in the pelvic and inguinal regions for the mesh placement. Instant documentation and video recording was done, with special emphasis on the fascial layers and the potential interfascial spaces in the retropubic and adjacent areas.

RESULTS

Four fascial layers were observed in the retropubic region, namely, (1) Retropubic fascia (in all cases of TEPP hernioplasty, i.e., N=68) covering the terminal part and tendon of the rectus abdominis muscle and in continuity of the Rectusial fascia, the condensed thickened posterior epimysium of the rectus abdominis muscle, as reported earlier by the author,[9] (2) Complete posterior rectus sheath (N=14), which was double-layered in one case, as reported earlier by the author,[6,10] (3) Transversalis fascia (in all cases, i.e., N=68), which was always found single-layered but at times diaphanous, as reported earlier by the author,[7,11] and (4) Preperitoneal fascia (in all cases of TEPP hernioplasty, i.e., N=68), which was double-layered in 12 cases [Table 1], as reported earlier by the author.[8,11]

In our study, the transversalis fascia was found invariably single-layered in all of the 68 cases of the inguinal hernia operated. However, seven combinations of twin anatomic variations of the posterior rectus sheath and preperitoneal fascia were recorded, namely, (1) single-layer incomplete posterior rectus sheath and single-layer preperitoneal fascia (64.7%); (2) double-layer incomplete posterior rectus sheath and single-layer preperitoneal fascia (2.9%); (3) single-layer incomplete posterior rectus sheath and double-layer preperitoneal fascia (4.4%); (4) double-layer incomplete posterior rectus sheath and double-layer preperitoneal fascia (7.4%); (5) single-layer complete posterior rectus sheath and single-layer preperitoneal fascia (13.2%); (6) single-layer complete posterior rectus sheath and double-layer preperitoneal fascia (4.4%); (7) double-layer complete posterior rectus sheath and double-layer preperitoneal fascia (1.5%) [Table 2].

In clinical situation 1 (N=44) with a single-layered incomplete posterior rectus sheath and a single-layered preperitoneal fascia [Figure 1], there were found four fissile potential retropubic spaces, namely, (1) Classical retropubic space (Space I) bounded anteriorly by the Rectusial fascia & pubic bone and posteriorly by the transversalis fascia, (2) Surgical preperitoneal retropubic space (Space II) bounded anteriorly by the transversalis fascia and posteriorly by the preperitoneal fascia, and (3) Anatomical preperitoneal retropubic space (Space III) bounded anteriorly by the preperitoneal fascia and posteriorly by the parietal peritoneum, (4) True anatomical retropubic space (Space IV) bounded anteriorly by the rectus abdominis tendon & pubic bone and posteriorly by the Rectusial fascia [Figure 1].

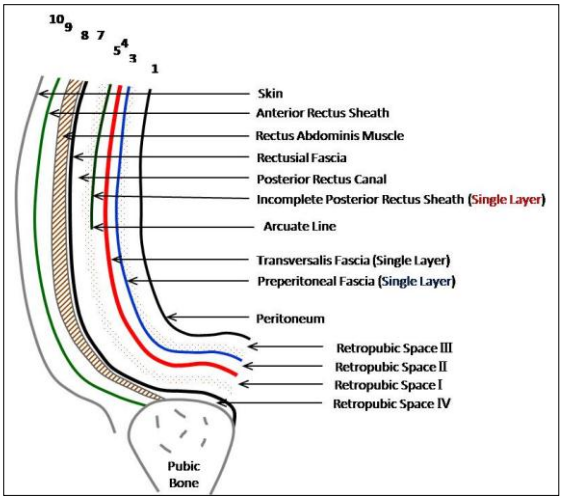

Figure 1: Four Retropubic spaces in presence of a single-layered preperitoneal fascia (3), a single-layered transversalis fascia (4) and a single-layered incomplete posterior rectus sheath (5); Retropubic space I, Classical retropubic space (Retzius); Retropubic space II, Surgical preperitoneal retropubic space; Retropubic space III, Anatomical preperitoneal retropubic space; Retropubic space IV, True anatomical retropubic space.

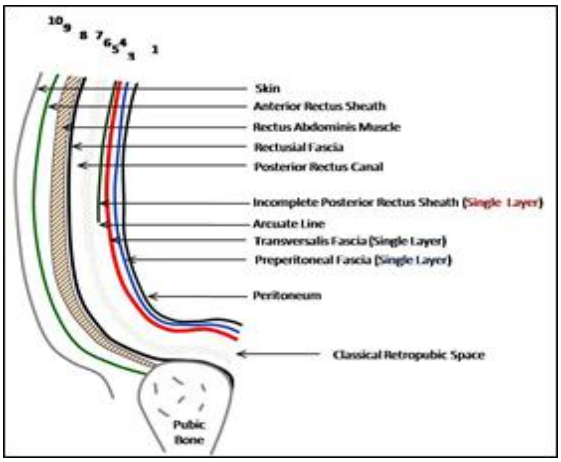

Figure 2: Boundaries of the classical retropubic space in presence of a single-layered preperitoneal fascia (3), a single-layered transversalis fascia (4) and a single-layered incomplete posterior rectus sheath (5).

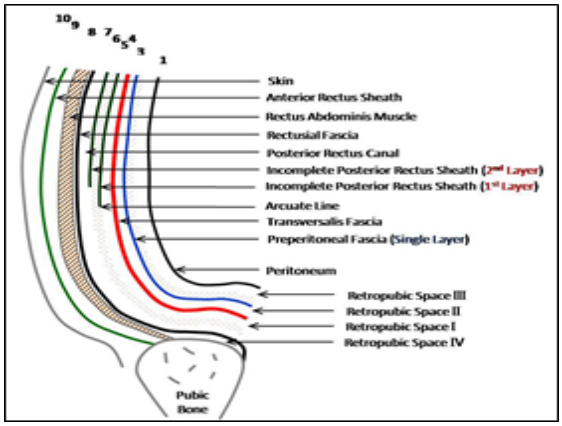

Figure 3: Four Retropubic spaces in presence of a single-layered preperitoneal fascia (3), a single-layered transversalis fascia (4) and a double-layered incomplete posterior rectus sheath (5-6); Retropubic space I, Classical retropubic space (Retzius); Retropubic space II, Surgical preperitoneal retropubic space; Retropubic space III, Anatomical preperitoneal retropubic space; Retropubic space IV, True anatomical retropubic space.

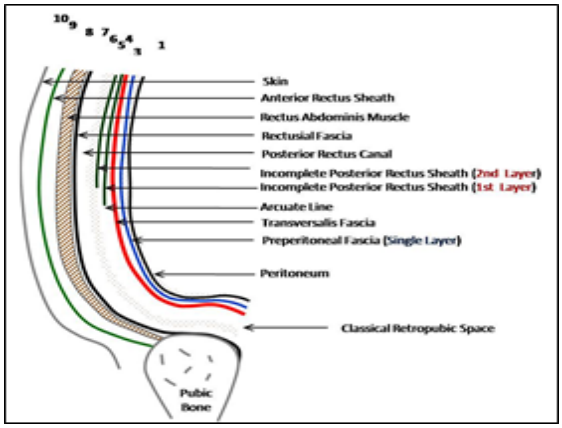

Figure 4: Boundaries of the classical retropubic space in presence of a single-layered preperitoneal fascia (3), a single-layered transversalis fascia (4) and a double-layered incomplete posterior rectus sheath (5-6).

In classical terms, the traditional Retzius space in the clinical situation 1 might be considered bounded posteriorly by three layers, viz., the single-layered transversalis fascia, the single-layered preperitoneal fascia and the parietal peritoneum [Figure 2].

In the clinical situation 2 with presence of the double-layered incomplete posterior rectus and the single-layered preperitoneal fascia (N=2) [Table 2], the second layer of the incomplete posterior rectus sheath (PRS) further divided the classical posterior rectus canal (upper part) into two potential spaces [Figure 3] but did not alter the configuration of the classical retropubic space [Figure 4].

In the clinical situation 3 with presence of the single-layered incomplete posterior rectus and the double-layered preperitoneal fascia (N=3) [Table 2], presence of the second layer of the double-layered preperitoneal fascia subdivided the preperitoneal retropubic space into two fissile potential spaces [Figure 5]; and in this situation, the traditional retropubic space was bounded posteriorly by four fascial layers, i.e., one layer of the transversalis fascia, two layers of the double-layered preperitoneal fascia and the parietal peritoneum [Figure 6].

In the clinical situation 4 with presence of the double-layered incomplete posterior rectus sheath and the double-layered preperitoneal fascia (N=5) [Table 2], presence of the second layer of the double-layered incomplete posterior rectus sheath (PRS) further divided the classical posterior rectus canal (upper part) into two potential spaces but it did not alter the configuration of retropubic space [Figure 7].

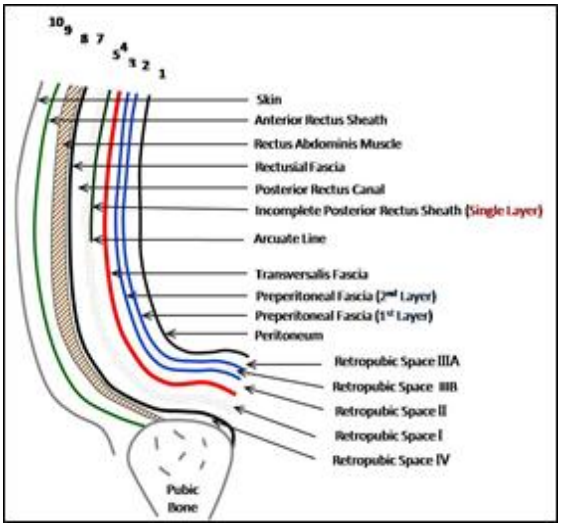

Figure 5: Five Retropubic spaces in presence of a double-layered preperitoneal fascia (2-3), a single-layered transversalis fascia (4) and a single-layered incomplete posterior rectus sheath (5); Retropubic space I, Classical retropubic space (Retzius); Retropubic space II, Surgical preperitoneal retropubic space; Retropubic space III A, Anatomical preperitoneal retropubic space; Retropubic spaces IIIB, Posterior intra-fascial retropubic space; Retropubic space IV, True anatomical retropubic space.

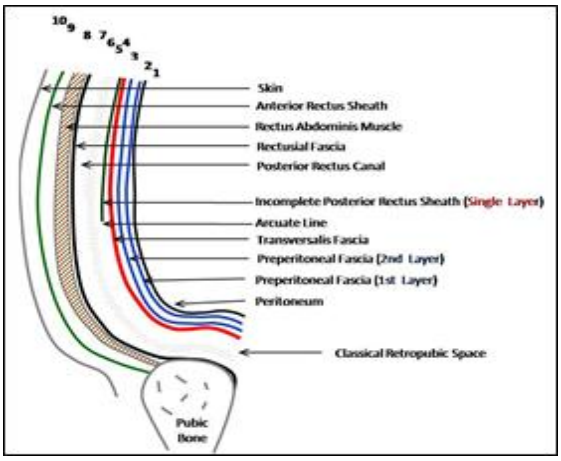

Figure 6: Boundaries of the classical retropubic space in presence of a double-layered preperitoneal fascia (2-3), a single-layered transversalis fascia (4) and a single-layered incomplete posterior rectus sheath (5-6).

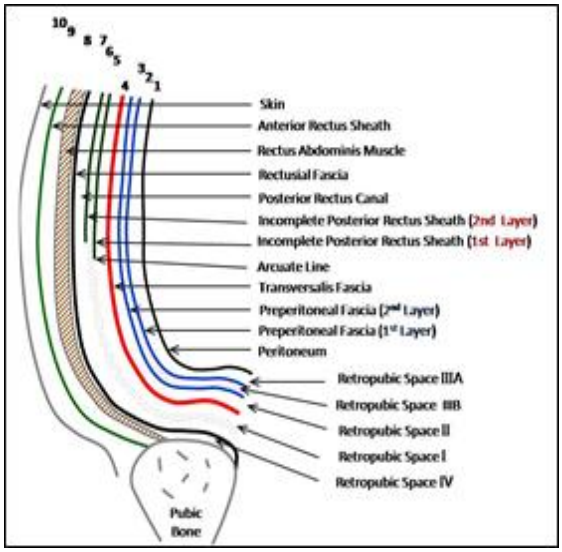

Figure 7: Five Retropubic spaces in presence of a double-layered preperitoneal fascia (2-3), a single-layered transversalis fascia (4) and a double-layered incomplete posterior rectus sheath (5); Retropubic space I, Classical retropubic space (Retzius); Retropubic space II, Surgical preperitoneal retropubic space; Retropubic space IIIA, Anatomical preperitoneal retropubic space; Retropubic space IIIB, Posterior intra-fascial retropubic space; Retropubic space IV, True anatomical retropubic space.

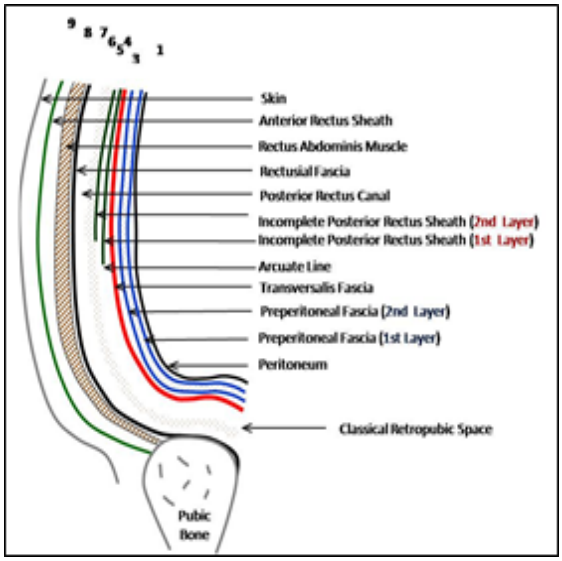

Figure 8: Boundaries of the classical retropubic space in presence of a double-layered preperitoneal fascia (2-3), a single-layered transversalis fascia (4) and a double-layered incomplete posterior rectus sheath (5-6).

However, presence of the second layer of the double-layered preperitoneal fascia in the clinical situation 4 subdivided the preperitoneal space into two fissile potential spaces [Figure 7]. In this situation, the traditional retropubic space was bounded posteriorly by the four fascial layers, i.e., one layer of the transversalis fascia, two layers of the double-layered preperitoneal fascia and the parietal peritoneum [Figure 8].

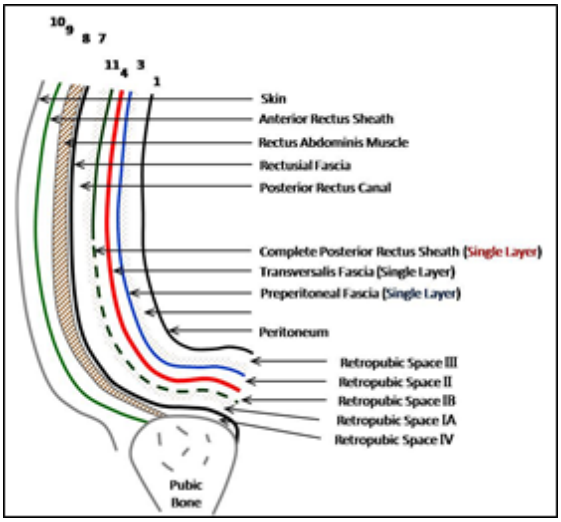

Figure 9: Five Retropubic spaces in presence of a single-layered preperitoneal fascia (3), a single-layered transversalis fascia (4) and a single-layered complete posterior rectus sheath (11); Retropubic space IA, Classical (Retzius) ante-rectus retropubic space; Retropubic space IB, Retro-rectus retropubic space; Retropubic space II, Surgical preperitoneal retropubic space; Retropubic space III, Anatomical preperitoneal retropubic space; Retropubic space IV, True anatomical retropubic space.

In the clinical situation 5 with presence of the single-layered complete posterior rectus sheath and the single-layered preperitoneal fascia (N=10) [Table 2] [Figure 9], presence of the complete posterior rectus sheath further subdivided the classical retropubic space into two potential spaces, thereby leading to formation of a total of five fissile potential spaces in the retropubic region [Figure 9]; and in this situation, the traditional retropubic was found bounded by four fascial layers, i.e., one layer of the single-layered complete posterior rectus sheath, the transversalis fascia, one layer of the single-layered preperitoneal fascia and the parietal peritoneum [Figure 10].

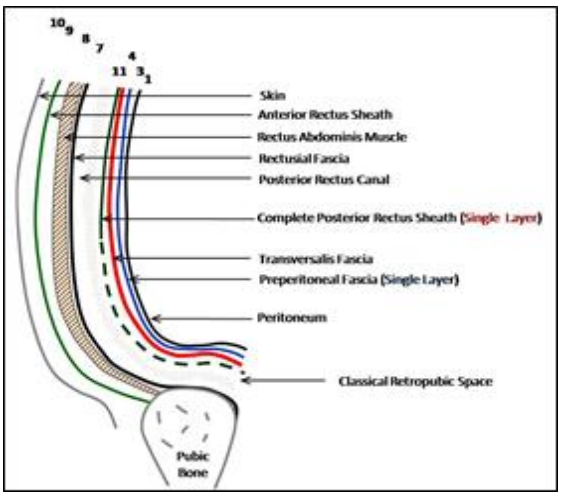

Figure 10: Boundaries of the classical retropubic space in presence of a single-layered preperitoneal fascia (3), a single-layered transversalis fascia (4) and a single-layered complete posterior rectus sheath (11).

In the clinical situation 6 with presence of the single-layered complete posterior rectus sheath and the double-layered preperitoneal fascia (N=3) [Table 2], presence of the second layer of the double-layered preperitoneal fascia further subdivided the anatomical preperitoneal space into two more fissile potential spaces, thereby resulting in the formation of a total of six fissile potential retropubic spaces [Figure 11]; and in this situation, the traditional retropubic space was found bounded by five fascial layers, i.e., one layer of the single-layered complete posterior rectus sheath, one layer of the transversalis fascia, two layers of the double-layered preperitoneal fascia and the parietal peritoneum [Figure 12].

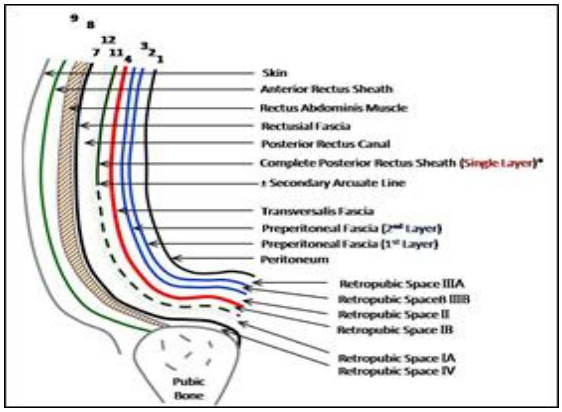

Figure 11: Six Retropubic spaces in presence of a double-layered preperitoneal fascia (2-3), a single-layered transversalis fascia (4) and a single-layered complete posterior rectus sheath (11); Retropubic space IA, Classical (Retzius) ante-rectus retropubic space; Retropubic space IB, Retro-rectus retropubic space; Retropubic space II, Surgical preperitoneal retropubic space; Retropubic space IIIA, Anatomical preperitoneal retropubic space; Retropubic space IIIB, Posterior intra-fascial retropubic space; Retropubic space IV, True anatomical retropubic space.

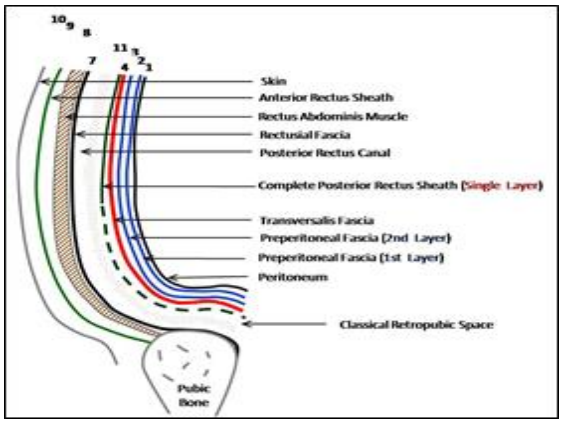

Figure 12: Boundaries of the classical retropubic space in presence of a double-layered preperitoneal fascia (2-3), a single-layered transversalis fascia (4) and a single-layered complete posterior rectus sheath (11).

In the clinical situation 7 with simultaneous presence of a double-layered complete posterior rectus sheath and a double-layered preperitoneal fascia as was documented in only one case in our study of the 68 inguinal hernias [Table 1 and 2], a total of seven fissile potential retropubic spaces were recognizable [Figure 13]

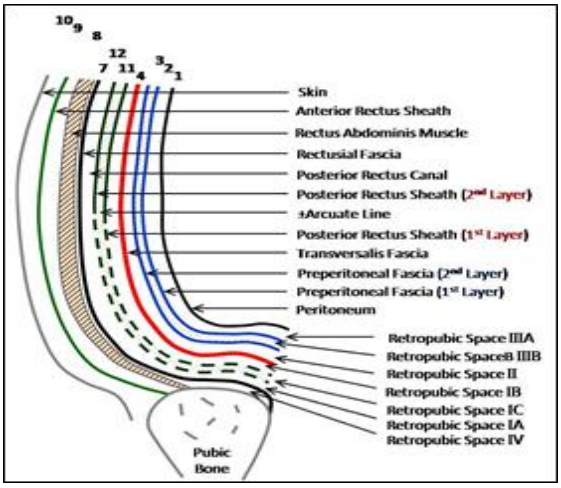

Figure 13: Seven retropubic spaces in presence of a double-layered preperitoneal fascia (2-3), a single-layered transversalis fascia (4) and a double-layered complete posterior rectus sheath (11-12); Retropubic space IA, Classical (Retzius) ante-rectus retropubic space; Retropubic space IB, Retro-rectus retropubic space; Retropubic space IC, Anterior intra-fascial retropubic space; Retropubic space II, Surgical preperitoneal retropubic space; Retropubic space IIIA, Anatomical preperitoneal retropubic space; Retropubic space IIIB, Posterior intra-fascial retropubic space; Retropubic space IV, True anatomical retropubic space.

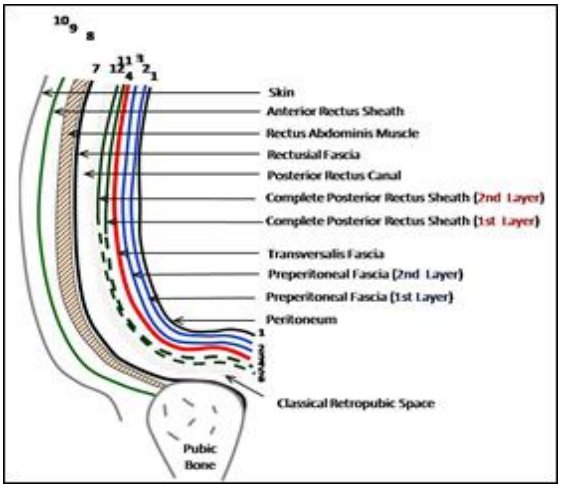

Figure 14: Boundaries of the classical retropubic space in presence of a double-layered preperitoneal fascia (2-3), a single-layered transversalis fascia (4) and a double-layered complete posterior rectus sheath (11-12).

In the clinical situation 7, the traditional retropubic space was found bounded by six fascial layers, i.e., two layers of the double-layered complete posterior rectus sheath, one layer of the transversalis fascia, two layers of the double-layered preperitoneal fascia and the parietal peritoneum [Figure 14].

Table 1: Distribution of Posterior Rectus Sheath, Transversalis Fascia and Preperitoneal Fascia Observed during TEPP Hernioplasty (N=68) for Inguinal Hernia

S. No.	Anatomical Structure	Single Layer N (%)	Double Layer N (%)	Total N (%)	Total N (%)
1	Incomplete PRS	47 (87.0)	7 (13.0)	54 (79.4)	68 (100)
2	Complete PRS	13 (92.9)	1 (7.1)	14 (20.6)	
3	Transversalis Fascia	68 (100)	0	68 (100)	
4	Preperitoneal Fascia	56 (82.4)	12 (17.6)	68 (100)	

TEPP, total extraperitoneal preperitoneal hernioplasty; PRS, posterior rectus sheath

Table 2: Combinations of Twin Anatomic Variations of Posterior Rectus Sheath and Preperitoneal Fascia Observed during TEPP Hernioplasty (N=68) for Inguinal Hernia.

S. No.	Clinical Situation*	Hernias** (N)	Hernias** (%)	Spaces† N
1	Single-Layer IC-PRS + Single-Layer PPF	44	64.7	4
2	Double-Layer IC-PRS + Single-Layer PPF	2	2.9	4
3	Single-Layer IC-PRS + Double-Layer PPF	3	4.4	5
4	Double-Layer IC-PRS + Double-Layer PPF	5	7.4	5
5	Single-Layer C-PRS + Single-Layer PPF	10	14.7	5
6	Single-Layer C-PRS + Double-Layer PPF	3	4.4	6
7	Double-Layer C-PRS + Double-Layer PPF	1	1.5	7
8	Double-Layer C-PRS + Single-Layer PPF¶	0	0	6¶
	Total	68	100	

TEPP, total extraperitoneal preperitoneal hernioplasty; PRS, posterior rectus sheath; IC-PRS, incomplete posterior rectus sheath; C-PRS, complete posterior rectus sheath; PPF, preperitoneal fascia; *Indicates twin anatomic variations present in the same individual; **Inguinal hernias; †Fissile potential retropubic spaces; ¶Hypothetical possibility;

In nutshell, multiple potential spaces were observed in the retropubic region, ranging from 4 to 7 in number; a total of four fissile potential retropubic spaces were recognized in 46 cases of the TEPP hernioplasty when the posterior rectus sheath was incomplete and preperitoneal fascia & transversalis were single-layered [Figure 1]; a total of five fissile potential retropubic spaces were observed when the preperitoneal fascia was double-layered along with presence of either a single-layered or double-layered incomplete posterior rectus sheath [Figure 5 and 7]; a total of five fissile potential retropubic spaces were also observed when the preperitoneal fascia was single-layered along with presence of a single-layered complete posterior rectus sheath [Figure 11]; a total of six fissile potential retropubic spaces were observed when the preperitoneal fascia was double-layered along with presence of a single-layered complete posterior rectus sheath [Figure 6]; and a maximum of seven fissile potential retropubic spaces were recognized in presence of a double-layered complete posterior rectus sheath and a double-layered preperitoneal fascia at the same time [Figure 13].

DISCUSSION

When asked to comment, Matthias Kux spoke the mind of a traditional surgeon that "What can a surgeon's view of today add to our understanding of groin anatomy since that area has been explored and described so extensively by the great surgeon-anatomists of the past."[13] However, modern technologies and newer surgical approaches provide new vision of structures known for centuries as rightly pointed out in 2000 by Avisse et al.[14] Matthias Kux opined further that the "Therefore, it (surgeon's view) must be different from the view that is obtained from a cadaveric dissection".[13]

The retropubic space of Retzius is always taught to be bounded by the transversalis fascia. However, despite the apparent accord in the old and recent textbooks of Anatomy, there has been conflicting views regarding the Retzius space.[3] Many observers have given different boundaries for this space,[15-20] necessitating re-evaluation of the retropubic anatomy.[3]

Way back in 1948, Mark Hayes documented for the first time that "In view of the several fasciae and interfascial clefts present, it is no longer possible to consider the "space of Retzius" as a single anatomical entity."[3] He suggested a novel concept of multiple fascia1 spaces in the retropubic region, namely in his own words, "the suprapubic space bounded ventrally by the rectus abdominis muscle, dorsally by parietal fascia, caudally by the pubis. Next in order is the space bounded ventrally by the parietal fascia, dorsally by the umbilical prevesical fascia and for which the term umbilical vesical prefascial space is suggested. This space has dorsal extensions guided by the dorsal limbs of the umbilical prevesical fascia to the region of the pelvic side of the acetabulum. The next space to consider is bounded ventrally by the umbilical prevesical fascia

and dorsally by the umbilical vesical fascia, the umbilical vesical interfascial space. Another more dorsal space is the supravesical space, previously described (p. 138). The most dorsal space is bounded by the umbilical vesical fascia ventrally and the peritoneum dorsally, the umbilical vesical retrofascial space."[3]

Pages 137-138 of Hayes' Thesis read:[3] "The umbilical vesical fascia [Figure 2] is a specialization of extraperitoneal connective tissue enclosing the bladder and associated structures. It is a triangularly disposed fascia [Figure 1], the apex of which may reach to the umbilicus and encloses the urachus and both obliterated hypogastric arteries. Caudally the fascia ensheathes the bladder, seminal vesicles, and prostate gland [Figure 1 and 2]. Local condensations of this fascia form the lateral true ligaments of the bladder and the puboprostatic ligaments. At the apex of the bladder, the umbilical vesical fascia can be opened, demonstrating a conical potential space, the base of which is bladder musculature, the supravesical space [Figure 2]." [3]

Unfortunately, Hayes' thesis on the abdominopelvic fascia,[3] a classic in its own, remained largely unknown to the anatomists and surgeons alike, and on the other hand, despite the increasing popularity of the laparoscopic hernioplasty worldwide, no other study on multiple potential retropubic spaces is available in the English literature to the best of my knowledge and search except a recent report of the author,[4] published before coming across the Hayes' thesis by chance during casual net surfing.[3]

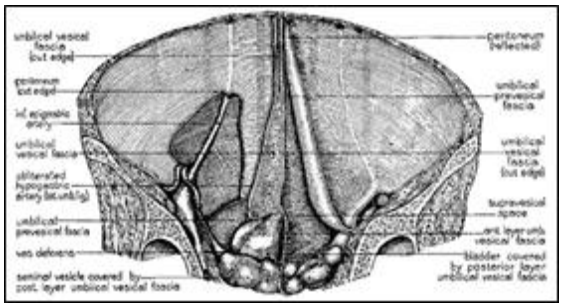

Figure 15: Hayes' Fig. 1: 'Schematic view of the ventral abdominal wall viewed from within. On the right nearly all the umbilical vesical fascia has been removed, revealing the umbilical prevesical fascia. On the left, only a part of the umbilical vesical fascia has been removed to show its distribution enveloping the bladder, the ductus deferens, and the seminal vesicles.

Our live surgical observations confirmed the Hayes' cadaveric findings of multiple potential retropubic spaces instead of a single anatomical of Retzius space. Firstly,[3] a true anatomical retropubic space (Space IV) was found bounded anteriorly by the rectus tendon & pubic bone and posteriorly by the Rectusial fascia [Figure 1,3,5,7,9,11,13]; this space was not recognizable in the Hayes' cadaveric dissections.[3] Secondly, the Classical retropubic space (Space I) bounded anteriorly by the Rectusial fascia & pubic bone and posteriorly by the transversalis fascia [Figure 1-16], corresponded to the Hayes' most ventral suprapubic space.[3] Thirdly, the Surgical preperitoneal retropubic space (Space II) bounded anteriorly by the transversalis fascia and posteriorly by the preperitoneal fascia [Figure 1,3,5,7,9,11,13 and 15-16], corresponded to the Hayes' umbilical vesical prefascial space.[3] Fourthly, the Anatomical preperitoneal retropubic space (Space III) bounded anteriorly by the preperitoneal fascia and posteriorly by the parietal peritoneum [Figure 1,3,5,7,9,11,13 and 15-16], corresponded to the Hayes' umbilical vesical retrofascial space.[3]

Figure 16: Hayes' Fig. 2: 'Semischematic drawing of a pelvic dissection to show the extraperitoneal migration fasciae of the urogenital apparatus and of the rectum. The apex of the bladder has been removed to demonstrate the enveloping character of this fascia and the location of the supravesical space. The continuities around ureter and vas deferens are shown.'

In presence of the double-layered preperitoneal fascia as reported earlier by the author,[9,11] there was found a potential space (Space IIIB) between the two layers of the double-layered preperitoneal fascia [Figure 5,7,11,13], which corresponded to the Hayes' umbilical vesical interfascial space and its upward extension, i.e., the Hayes' supravesical space [Figure 15 and 16].[3]

In presence of a complete posterior rectus sheath as reported earlier by the author as well as by others,[6,9,21-25] the complete posterior rectus sheath further divided the classical retropubic space (Space I) into two fissile potential spaces (Space IA and IB) [Figure 9 and 11], or it might mean that the classical retropubic space was bounded posteriorly by both the complete posterior rectus sheath and the transversalis fascia, in addition to the preperitoneal fascia (single/double-layered) and the parietal peritoneum [Figure 10 and 12]. Furthermore, in presence of the double-layered complete posterior rectus sheath,[9,24] another potential space (Space IC) was present in between its two layers [Figure 13]. In classical terms the traditional retropubic space was bounded posteriorly by the double-layered complete posterior rectus sheath and the transversalis fascia, in addition to the preperitoneal fascia (single/double-layered) and the parietal peritoneum [Figure 14].

In 1948, Mark Hayes[3] tried to explain the formation of multiple fascial layers in the parieto-peritoneal space that "Within the abdominopelvic cavity, three basic embryonic tissues are concerned in the evolution of adult fasciae: the young mesenchymal tissue intimately associated with the developing musculature of the parietes ; the loose mesenchymal tissue ubiquitously distributed between the developing intrinsic fascia of the muscles and the maturing celomic epithelium; and the celomic epithelium itself. The growth and modification of these three developing tissues produce the completely formed fasciae, and their developmental history is basic to the adult disposition of fasciae."

In terms of the traditional textbook teaching with no recognition of the preperitoneal fascia, the classical retropubic space was bounded posteriorly by the transversalis fascia and the parietal peritoneum only [Figure 17]. However, it has now been well established beyond doubt that the preperitoneal fascia is a definite anatomical entity,[8,11,21,23,26-32] and therefore, in the classical terms, the traditional retropubic space (Space I) was found bounded posteriorly by atleast three fascial layers, viz., the transversalis fascia, the preperitoneal fascia and the parietal peritoneum [Figure 1], a clinical situation observed during 65% of the TEPP hernioplasties performed in the present study.

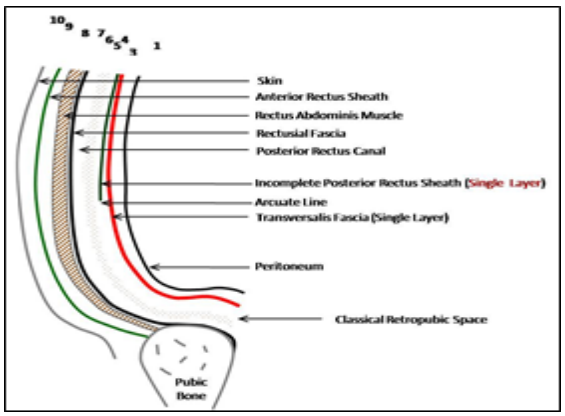

Figure 17: Boundaries of the classical retropubic space (Retzius) in presence of a single-layered transversalis fascia (4) and a single-layered incomplete posterior rectus sheath (5) but with non-recognition or non-realization of the preperitoneal fascia.

In the clinical situation 1 (N=44) with single-layer incomplete posterior rectus sheath and single-layer preperitoneal fascia [Figure 1], the preperitoneal retropubic space in classical terms was appeared to be bounded anteriorly by two fascial layers, i.e., the transversalis fascia and the preperitoneal fascia, and in this situation, the preperitoneal fascia was likely to be confused as the so-called 'posterior lamina' of the transversalis fascia (proper); and moreover, the traditional Retzius space might be considered bounded posteriorly by three layers, viz., the single-layered transversalis fascia, the single-layered preperitoneal fascia and the parietal peritoneum [Figure 1].

In the clinical situations 2 and 4 with presence of double-layer incomplete posterior rectus sheath (N=7) [Table 2], the posterior rectus canal just below the umbilicus was, in classical terms, bounded posteriorly by the five and six layers respectively, i.e., the two layers of the incomplete posterior rectus sheath, the transversalis fascia, the one and two layers of the preperitoneal fascia and the parietal peritoneum [Figure 4 and 8]. Presence of a double-layered incomplete posterior rectus sheath did not affect the anatomic disposition of the retropubic space, but in this situation, the second layer of the incomplete posterior rectus sheath was likely to be confused as the so-called 'anterior lamina' of the transversalis fascia (proper); and the differential ending of the two layers of the incomplete posterior rectus sheath has been regarded as the cause for the formation of the double arcuate lines.[12,33,34]

In presence of the clinical situations 3 and 4 with presence of an incomplete posterior rectus sheath (single/double-layered) and a double-layered preperitoneal fascia [Figure 5 and 7], the conventional/anatomical preperitoneal retropubic space was, in classical terms, bounded anteriorly by three layers, i.e., the two layers of the double-layered preperitoneal fascia and the single layer of the transversalis fascia [Figure 18]. In the later situation, the traditional Retzius space was bounded posteriorly by four layers, viz., the transversalis fascia, the two layers of the double-layered preperitoneal fascia and the parietal peritoneum [Figure 6, 8 and 18]; and moreover, the double-layered preperitoneal fascia was likely to be confused as the 'double-layer posterior lamina' of the transversalis fascia (proper), although the two fasciae were found distinctly separate with their own neurovascular supply as has also been documented by others,[21,23,26-32] and there was found present an easily cleavable avascular plane of dissection between them in all cases of the present study.

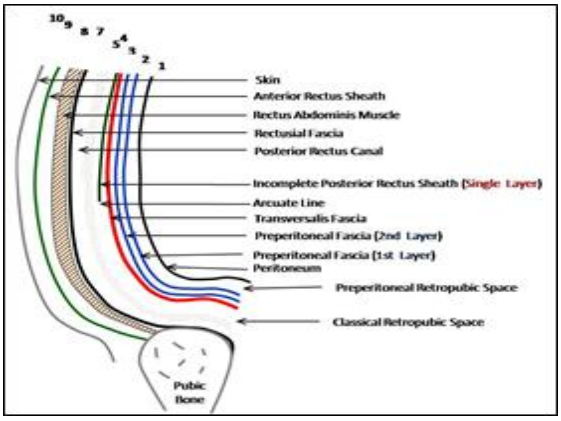

Figure 18: Boundaries of the classical retropubic space (Retzius) and the true anatomical preperitoneal space in presence of a double-layered preperitoneal fascia (2-3) and a single-layered incomplete posterior rectus sheath (5).

In the clinical situation 4 with presence of a double-layered incomplete posterior rectus sheath and a double-layered preperitoneal fascia (N=5) [Table 2], the posterior rectus canal just below the umbilicus was, in classical terms, bounded posteriorly by the six layers, i.e., the two layers of the double-layered incomplete posterior rectus sheath, the transversalis fascia, the two layers of the double-layered preperitoneal fascia and the parietal peritoneum (Fig. 8); however, the traditional Retzius space was, in classical terms, bounded posteriorly by only four fascial layers, viz., the transversalis fascia, the two layers of the double-layered preperitoneal fascia and the parietal peritoneum [Figure 8].

In the clinical situation 5 with presence of a single-layered complete posterior rectus sheath and a single-layered preperitoneal fascia (N=10) [Table 2], the whole of the posterior rectus canal below the umbilicus was, in classical terms, bounded posteriorly either by three layers if the preperitoneal fascia is not recognized, namely, one layer of the single-layered complete posterior rectus sheath, one layer of the transversalis fascia and the parietal peritoneum [Figure 19] or by four layers when the preperitoneal fascia is recognized as was observed in 10 cases in our series in the clinical situation 5 [Table 2], i.e., one layer of the single-layered complete posterior rectus sheath, one layer of the transversalis fascia, one layer of the single-layered preperitoneal fascia and the parietal peritoneum [Figure 10]. In the later situation, the Retzius space had an anatomic disposition similar to that of the posterior rectus canal, i.e., it was, in classical terms, bounded posteriorly by the four fascial layers, viz., the single-layered complete posterior rectus sheath, the transversalis fascia, the single-layered preperitoneal fascia and the parietal peritoneum [Figure 10].

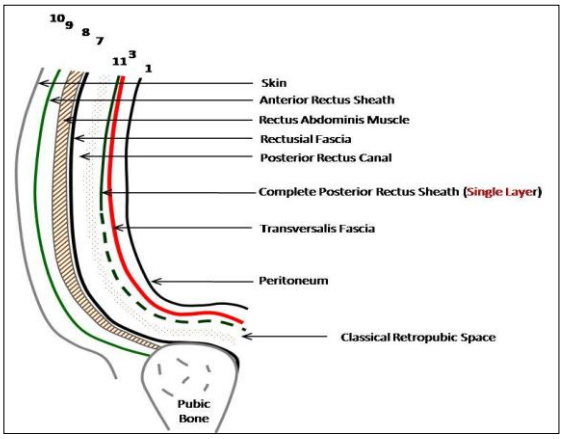

Figure 19: Boundaries of the classical retropubic space in presence of a single-layered transversalis fascia (4) and a single-layered complete posterior rectus sheath (11) but with non-recognition or non-realization of the preperitoneal fascia.

The conventional/anatomical preperitoneal retropubic space was bounded anteriorly by three layers, namely, the single-layered preperitoneal fascia, the single-layered transversalis fascia and the single-layered complete posterior rectus sheath [Figure 10]; moreover, the complete posterior rectus sheath, especially when attenuated, was very likely to be confused as the 'anterior lamina' of the transversalis fascia (proper) especially in early phase of the TEPP learning curve as was experienced by the author in the present study and similar experience had also been reported by others.[23,24]

In the clinical situation 6 with presence of single-layered complete posterior rectus sheath and double-layered preperitoneal fascia as was documented in 3 cases of the present series [Table 2], the Retzius space as well as the posterior rectus canal upto the umbilicus was, in classical terms, bounded posteriorly by five fascial layers, i.e., one layer of the complete posterior rectus sheath, one layer of the transversalis fascia, two layers of the double-layered preperitoneal fascia and the parietal peritoneum [Figure 14]; moreover, the conventional/anatomical preperitoneal retropubic space was bounded anteriorly by four layers, namely, the two layers of the double-layer preperitoneal fascia, the transversalis fascia and one layer of the single-layer complete posterior rectus sheath [Figure 12].

In the clinical situation 7 with presence of double-layered complete posterior rectus sheath and double-layered preperitoneal fascia as was documented in 1 case of the present series [Table 2], the Retzius space as well as the posterior rectus canal upto the umbilicus was, in classical terms, bounded posteriorly by six fascial layers, i.e., the two layers of the double-layered complete posterior rectus sheath, one layer of the transversalis fascia, the two layers of the double-layered preperitoneal fascia and the parietal peritoneum [Figure 14]. The double-layered complete posterior rectus sheath, especially when attenuated, was very likely to be confused as the 'double-layered anterior lamina' of the transversalis fascia (proper).

In the light of the various anatomic variations observed in the present study, the combination of a double-layered complete posterior rectus sheath and a single-layered preperitoneal fascia was hypothetically possible and expected [Table 2 & Figure 20], but such an anatomic disposition was not really documented by the author in any individual in the present series. However, a total of six fissile potential spaces would have been recognizable in the retropubic region during this theoretical possibility [Figure 20].

To conclude, the present study of laparoscopic live surgical anatomy confirmed the cadaveric observations of Mark Hayes,[3] that contrary to the common belief and teaching of a single retropubic space of Retzius, multiple fissile interfascial clefts/spaces/planes are present in the retropubic region ranging from 4 to 7 in number due to the presence of a plethora of fascial layers, and because

of this multilayered fascial anatomy, the clinical observations of Edward Felix (2009) was proved correct in the present study that "Initially, the dissection of the extraperitoneal space in the TEP approach tended to be difficult, confusing and therefore hard to learn".[35] The author feels strongly that probably each one of the previous investigators,[3,15-20] was correct in his own right about the conflicting boundaries of the Retzius space, depending upon the anatomical plane he really worked in. Such a plausible explanation would really realize the honourable tributes to the previous dedicated investigators with the due recognition of their hard diligent academic work.

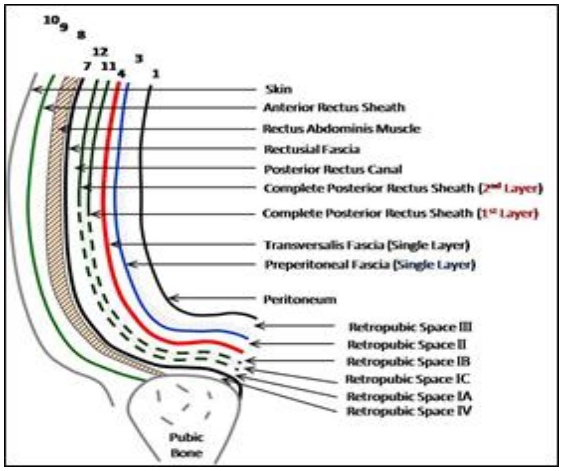

Figure 20: Six retropubic spaces in presence of a single-layered preperitoneal fascia (3), a single-layered transversalis fascia (4) and a double-layered complete posterior rectus sheath (11-12); Retropubic space IA, Classical (Retzius) ante-rectus retropubic space; Retropubic space IB, Retro-rectus retropubic space; Retropubic space IC, Anterior intra-fascial retropubic space; Retropubic space II, Surgical preperitoneal retropubic space; Retropubic space III, Anatomical preperitoneal retropubic space; Retropubic space IV, True anatomical retropubic space.

Thus re-evaluation of the retropubic anatomy in general and the Retzius space in particular is necessitated based on the present findings of the laparoscopic live surgical anatomy as was also suggested originally by Mark Hayes way back in 1948.[3] This is particularly true for the laparoscopic TEPP surgeon who works in the interfascial preperitoneal planes in a limited closed space, and therefore, s/he must be aware of the plethora of these multiple retropubic spaces as s/he is often lost into these spaces, especially during the learning phase of TEPP hernioplasty, resulting in a messy frustrating dissection.

CONCLUSION

During laparoscopic total extra-peritoneal preperitoneal (TEPP) hernioplasty for inguinal hernia, multiple potential spaces were observed in the retropubic region, ranging from 4 to 7 in number, contrary to the general belief and traditional textbook teaching of the Retzius space as a single anatomical entity. Four potential retropubic spaces were present in all 68 cases of inguinal hernia, namely, (1) true anatomical/prefascial retropubic space, (2) classical/traditional retropubic space (Retzius space), (3) surgical preperitoneal retropubic space, and (4) anatomical preperitoneal retropubic space. Number of the potential retropubic spaces was more ranging from 5 to 7 in presence of the complete posterior rectus sheath and/or doubling of the fascial layer(s). Presence of several fascial layers and interfascial spaces made the surgical anatomy and technique of the laparoscopic total extra-peritoneal preperitoneal (TEPP) hernioplasty complex and hard to learn, leading to its unpopularity. The study proved that the newer surgical approaches provide new vision of the structures known for centuries as declared by Avisse et al in 2000.[14] However, contrary to the general belief as suggested in 2002 by Kux,[3] the surgeon's view may not necessarily be always different from the cadaveric dissection view as was proved by the present laparoscopic surgical study fully supporting and confirming the meticulous cadaveric dissections of Mark Hayes.[3] Thus the present study warrants that the retropubic anatomy, especially the Retzius space, needs to be re-evaluated and re-defined as was originally suggested in 1948 by Mark Hayes,[3] for the anatomists and the practicing surgeons, especially the TEPP hernia surgeon to execute the laparoscopic procedure in a closed space with ease, rapidity and safety.

Acknowledgement

All figures except 15 and 16 and all tables are modified slightly and reproduced with permission from "Ansari, MM. Thesis for PhD (Surgery) titled – 'A Study of Laparoscopic Surgical Anatomy of Infraumbilical Posterior Rectus Sheath, Fascia Transversalis & Pre-Peritoneal Fat/Fascia during TEPP Mesh Hernioplasty for Inguinal Hernia', Aligarh Muslim University, Aligarh, India,2016'. Figures 15 and 16 are reproduced under the open access attribution from the doctoral thesis of Mark Hayes.[3]

REFERENCES

1. Baumann (1942): cited by: Diarra B, Stoppa R, Verhaeghe P, Mertl P. About prolongations of the urogenital fascia into the pelvis: An anatomic study and general remarks on the interparietal-peritoneal fasciae. Hernia 1997; 1: 191-196.
2. Retzius AA. Some remarks on the proper design of the semilunar lines of Douglas. Edinburgh Med J 1858; 3: 865-867.
3. Hayes MA. The Developmental Basis for the Continuity of the Fascial Planes the Abdomen and Pelvis, PhD Thesis (Anatomy), University of Michigan, Ann Arbor, USA, 1948, pp 137-138, 143-144. Published under title: Abdominopelvic Fascia. Accessed on: September 30, 2017.

(https://deepblue.lib.umich.edu/bitstream/handle/2027.42/49606/1000870105_ftp.pdf?sequence=1)

4. Ansari (2017a): Ansari MM. Retzius and Bogros Spaces: A Prospective Laparoscopic Study and Current Perspectives. Ann. Int. Med. Den. Res. 2017; 3(5): SG25-SG31. (DOI:10.21276/aimdr.2017.3.5.SG8)
5. Ansari (2013): Ansari MM. Effective Rectus Sheath Canal: Does It Affect TEP Approach for Inguinal Mesh Hernioplasty. Journal of Experimental and Integrative Medicine 2013; 3(1): 73-76.
6. Ansari (2014): Ansari MM. Complete posterior rectus sheath and total extra-peritoneal hernioplasty. Saudi Surgical Journal 2014; 2(4): 80-83.
7. Ansari (2015a): Ansari MM. Fascia Transversalis - A Study of Live Surgical Anatomy during Laparoscopic Total Extra-Peritoneal Hernioplasty. International Journal of Science and Research (IJSR) 2015; 4(8): 1788-1796.
8. Ansari (2015b): Ansari MM. Pre-Peritoneal Fascia/Fat – Laparoscopic Anatomy during Total Extra Peritoneal Hernioplasty. Int J Sci Appl Res 2015; 2(10): 01-05.
9. Ansari (2017b): Ansari MM. Rectusial Fascia: A New Entity of Laparoscopic Live Surgical Anatomy. Open Access Journal of Surgery 2017 April; 3(4): pp 1-5. DOI: 10.19080/OAJS.2017.03.555618
10. Ansari (2017c): Ansari MM. Posterior Rectus Sheath: A Prospective Study of Laparoscopic Live Surgical Anatomy during TEPP Hernioplasty. World Journal of Laparoscopic Surgery 2017 September-December; 10(3) (In Press). (www.wjols.com/AcceptedArticles.aspx)
11. Ansari (2017d): Ansari MM. Transversalis Fascia and Preperitoneal Fascia: A Laparoscopic Study of Live Surgical Anatomy during TEPP Hernioplasty – Final Report and Literature Review. Annals of International Medical and Dental Research (AIMDR) 2017;3(6):SG19-32. (http://www.aimdrjournal.com/pdf/vol3Issue6/SG4_OA_V3N6.pdf)
12. Ansari (2017e): Ansari MM. Arcuate Line of Douglas: A Prospective Study of Laparoscopic Live Surgical Anatomy during TEPP Hernioplasty. International Journal of Science and Research 2017; 6(6): 2348-2363. (https://www.ijsr.net/archive/v6i6/ART20174875.pdf)
13. Kux M. Anatomy of the groin: A view from the surgeon. In Robert J. Fitzgibbons Jr., A. Gerson Greenburg (eds.) Nyhus and Condon's Hernia, 5th Edition, Chapter 5, Philadelphia: Lippincott Williams & Wilkins, 2002, 45-54.
14. Avisse C, Delattre JF, Flament JB. The inguinofemoral area from a laparoscopic standpoint. History, anatomy, and surgical applications. Surg Clin North Am 2000; 80(1): 35-48.
15. Hyrtl J. Notiz uber das Cavum praeperitoneale Retzii in der vorderen Bauchwand des Menschen. Sitzungsber K Acad Wiss (Wien) 1858; 29: 259-264.
16. Charpy A. La gaine des muscles droits et la cavite prevesicale. Etudes d'anatomie appliquée, Paris: Bailliere, 1892.
17. Waldeyer W (ed.) Das Becken. Bonn: Cohen, 1899.
18. Rouviere H (ed.) Anatomie Humaine, Descriptive et Topographique. Paris: Masson & Co., 1924.
19. Hinman F (ed.) The principles and Practice of Urology. Philadelphia: Saunders, 1937.
20. Callander CL (ed.) Surgical Anatomy. 2nd Edition, Philadelphia: Saunders, 1939.
21. Anson BJ, Morgan EH, McVay CB. Surgical anatomy of the inguinal region based upon a study of 500 body halves. Surg Gynecol Obstet 1960; 111: 707–725.
22. Rizk NN. The arcuate line of the rectus sheath–does it exist? J Anat 1991; 175:1-6.
23. Arregui ME. Surgical anatomy of the pre-peritoneal fasciae and posterior transversalis fasciae in the inguinal region. Hernia 1997; 1: 101-110.
24. Spitz JD, Arregui ME. Laparoscopic Totally Extraperitoneal Repair for Inguinal Hernia (TEP) Part II. In: Robert Bendavid, Jack Abrahamson, Maurice E. Arregui, Jean B. Flament, Edward H. Phillips (eds.) Abdominal Wall Hernias: Principles and Management, 1st Edition, Chapter 70, New York: Springer-Verlag, 2001, pp. 472-482.
25. Mwachaka P, Odula P, Awori K, Kaisha. Variations in the Pattern of Formation of the Abdominis Rectus Muscle Sheath among Kenyans. Int J Morphol 2009; 27(4): 1025-1029.
26. Lampe EW. Special comment: Experiences with preperitoneal hernioplasty. In: Lloyd M. Nyhus, Robert E. Condon (eds.) Hernia. 1st Edition, JB Lippincott, Philadelphia, I964, pp 295-301.
27. Fowler R. The applied surgical anatomy of the peritoneal fascia of the groin and the "secondary" internal inguinal ring. Aust N Z J Surg. 1975; 45(1): 8-14. 13. 19.
28. Redman JF. The secondary internal ring: Applications to the surgery of the inguinal canal. Clinical Urology 1996; 155(1): 170-173.
29. Condon RE. The anatomy of the inguinal region and its relation to groin hernia. In: L. M. Nyhus, R. E. Condon (eds.) Hernia, 4th Edition, Philadelphia: Lippincott, 1995, pp. 16-72.
30. Memon MA, Quin TH, Cahill DR. Transversalis fascia: Historical aspects and its place in contemporary inguinal herniorrhaphy. J Laproendoscop Adv Surg Tech 1999; 9(3): 267-272.
31. Mirilas et al (2008): Mirilas P, Mentessedou A, SKandalais JE. Secondary internal inguinal ring and associated surgical planes: surgical anatomy, embryology, applications. J Am Coo Surg 2008; 206(3): 561-570.
32. Mirilas (2012): Mirilas P. Intertransversalis approach for laparoscopic urology: surgical anatomy concerns. Arch Surg 2012: 147(10): 980.
33. McVay CB, Anson BJ. Composition of the rectus sheath. The Anatomical Record 1940; 77(2): 213-225.
34. Woodburne RT, Burkel WE (eds.) Essentials of Human Anatomy. 8th Edition, New York: Oxford University Press, 1988, pp. 411-417.
35. Felix EL. Laparoscopic Inguinal Hernia Repair. In: Nathaniel J. Soper, Lee L. Swanstrom, W. Stephen Eubanks (eds.). Mastery of Endoscopic and Laparoscopic Surgery, 3rd Edition, Chapter 53, Philadelphia: Lippincott Williams & Wilkins, 2009, pp 523-537.

How to cite this article: Ansari MM. Retzius space: not a single anatomical entity: new insights simplified and illustrated in a laparoscopic study during TEPP hernioplasty for inguinal hernia. Ann. Int. Med. Den. Res. 2018; 4(1):SG63-SG73.

Source of Support: Nil, **Conflict of Interest:** None declared