

# Diagnostic Accuracy of Fine Needle Aspiration Cytology (FNAC) in the Diagnosis of the Common Neck Swellings

Manish Kumar<sup>1</sup>, Md. Tausiful Haque<sup>1</sup>

<sup>1</sup>Senior Resident, Department of ENT, Nalanda Medical College & Hospital, Patna, Bihar, India.

Received: March 2021

Accepted: April 2021

## ABSTRACT

**Background:** Fine-needle aspiration cytology (FNAC) is widely employed as an initial investigative tool in the diagnosis of various types of lesions in the body, neck swellings being one of them. To make accurate surgical interventions for these swelling, it is essential to make a preoperative assessment. The aim of this study was to find out diagnostic accuracy of FNAC in the diagnosis of the common neck swellings. **Methods:** Patients attending the department of ENT with complaint of neck swelling were included in the study. FNAC and histopathology was performed. The sensitivity, specificity and predictive values of the test were calculated. **Results:** The mean age was 50.5 (SD±8.70). Most of the patient complaint of neck swelling for 6 month of duration. Histopathologically, 7.1% patients had papillary carcinoma thyroid, 17.8% had pleomorphic adenoma and 21.4% had goitre. The accuracy of FNAC for papillary carcinoma thyroid, pleomorphic adenoma and goiter was 98.8%, 97.6% and 95.2% respectively. **Conclusion:** FNAC is a sensitive, specific, and accurate initial diagnostic test for the evaluation of patients with neck swellings.

**Keywords:** FNAC, histopathological examination, neck swellings.

## INTRODUCTION

Fine Needle Aspiration Cytology (FNAC) is a well-established and widely used method for both a preliminary and sometime final non-invasive pathologic diagnosis. FNAC is a simple and inexpensive diagnostic tool and should represent the standard of care in developing and resource-poor countries while maintaining its diagnostic usefulness in developed and advanced ones.<sup>[1]</sup>

Lesions in the head and neck region, presenting to the ENT specialist are good cases for FNAC, because of excellent accessibility. The modality of cytologic diagnosis has gained almost universal acceptability owing to its many inherent advantages, some of which are, good patient compliance, minimal discomfort, trauma and; invasiveness, cost effectiveness, rapidity, and the avoidance of surgery in situations where a conservative approach is more profitable.<sup>[2]</sup>

The various neck swellings are as follows: Inflammatory – Lymphadenopathy Lymphadenitis, Granulomatous disease, Sialadenitis / sialolithiasis; Congenital – Thyroglossal duct cyst, Branchial cleft anomaly, Dermoid cyst, Teratoma, Lymphangiomas, hemangiomas; Primary neoplasm of neck - Lymphoma (Hodgkin's and Non-Hodgkin's); Thyroid neoplasm, neoplasm of salivary glands,

neurogenic neoplasm, Paragangliomas and lipomas.<sup>[3]</sup>

To make an accurate and effective surgical intervention, it is essential to make a preoperative assessment of the nature of these lesions. The aim of study was to find out diagnostic accuracy of Fine Needle Aspiration Cytology (FNAC) in the diagnosis of the common neck swellings. Specific objective was to calculate sensitivity, specificity, Positive predictive value (PPV) and Negative predictive value (NPV) of FNAC in comparison with gold standard histopathology in neck swellings.

## MATERIALS AND METHODS

All the patients attending the department of ENT with complaint of neck swelling or complication of neck swelling, over a period of 12 month starting from March, 2019 to February, 2020 fulfilling the inclusion and exclusion criteria were included in the study. The study was conducted in the Department of ENT at Nalanda Medical College & Hospital, Patna, after taking permission from institutional ethical committee. Patients with complaints of neck swelling or complications of neck swelling were included in the study. Patients not willing to participate in the study, patients with cardiovascular instability, patient with bleeding diathesis or deranged coagulation profile and patient with subclinical neck swelling were excluded, patient with advanced staged carcinoma of neck and Patient with carotid body tumors were excluded.

A study performa was developed which was pretested. After taking written informed consent, detailed history and clinical examination of patient

### Name & Address of Corresponding Author

Dr. Md. Tausiful Haque  
Senior resident,  
Department of ENT,  
Nalanda Medical College & Hospital,  
Patna, Bihar, India.

*Kumar & Haque; (FNAC) in the Diagnosis of the Common Neck Swellings*

was elicited with special emphasis on neck swelling problem. A thorough systemic examination was done to rule out any other systemic disease. First we did the FNAC taking full precautions. Later we did histopathology. The data were recorded on a predesigned proforma and analysed statistically. It was analyzed using EpiInfo version-6 software. The sensitivity, specificity and predictive values of the test were calculated.

## RESULTS

The mean age was 50.5 (SD±8.70), most common age group in the present study was 41-60 yrs (40/84, 47.6%) of age. Gender wise, out of 84 patients, 32

(38.1%) were males while 52 (61.9%) were females. [Table1] Most (32.1%) of the patient complaint of neck swelling for 6 month of duration, followed by one year (27.4%), one to five years (23.8%), up to 1 month (9.5%) and more than five years (7.2%). [Figure 1] In this study, right side neck swelling was more (60.7%, 51/84) and in 4.7% (4/84) of cases the swelling was in midline.

Most of the swelling was arising from the thyroid tissue, then parotid, subcutaneous tissue, submandibular gland. Lymph nodes and the deep neck space were seen too. In the current study, the pleomorphic adenoma, and goiter constitute the maximum number. Rest were sialoadenitis and papillary carcinoma thyroid of the thyroid.

**Table 1: Age and gender wise frequency distribution of patient of neck swelling (n=84)**

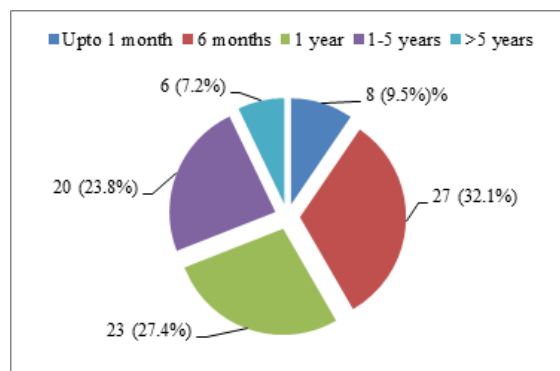
Age group	Male (%)	Female (%)	Total
<20 years	2 (6.3%)	11 (21.2%)	13 (15.5%)
21-40 years	11 (34.4%)	12 (23.1%)	23 (27.4%)
41-60 years	17 (53.1%)	23 (44.2%)	40 (47.6%)
>60 years	2 (6.2%)	6 (11.5%)	8 (9.5%)
Total	32 (100%)	52 (100%)	84 (100%)

**Table 2: Two by two table of the diagnosis of neck swellings by FNAC and Histopathology**

Neck swelling	FNAC	Histopathology		Total
		Positive	Negative	
Papillary Carcinoma	Positive	5	0	5
	Negative	1	78	79
Pleomorphic Adenoma	Positive	15	2	17
	Negative	0	67	67
Goiter	Positive	14	0	14
	Negative	4	66	70

**Table 3: Statistical accuracy of FNAC in comparison of histopathology (n=84)**

Neck swelling	Sensitivity (95% CI)	Specificity (95% CI)	PPV (95% CI)	NPV (95% CI)	Accuracy (95% CI)
Papillary Carcinoma	83.3% (35.8% - 99.6%)	100% (95.4%-100%)	100%	98.7% (92.9%- 99.8%)	98.8% (93.5%-99.9%)
Pleomorphic Adenoma	100% (78.2%-100%)	97.1% (89.9%-99.6%)	88.2% (65.7%-96.7%)	100%	97.6% (91.7%-99.7%)
Goiter	77.8% (52.4%-93.6%)	100% (94.6%-100%)	100%	94.3% (87.4%-97.5%)	95.2% (88.2%-98.7%)



**Figure 1: Duration of swelling (n=84)**

Histopathologically, 6 patients (7.1%) had papillary carcinoma thyroid, 15 patients (17.8%) had pleomorphic adenoma and 18 patients (21.4%) had goitre. So, FNAC & Histopathology were compared in about 46.4% (39/84) of the cases of the neck

swelling. [Table 2] For the FNAC of the papillary carcinoma thyroid, the sensitivity was 83.3%, specificity was 100%, PPV was 100%, NPV was 98.7%. For Pleomorphic adenoma the sensitivity was 100%, specificity 97.1%, PPV 88.2% and NPV was 100%. For goiter the sensitivity was 77.8%, specificity was 100%, PPV was 100% and NPV was 94.3%. The accuracy of FNAC for papillary carcinoma thyroid, pleomorphic adenoma and goiter was 98.8%, 97.6% and 95.2% respectively. [Table 3]

## DISCUSSION

The current study was performed in the total 84 patients in one year of time period. Out of 84 patients, 32 were males while 52 were females, and male: female ratio was 1:1.62. Recently Kumar A et al. reported male to female ratio as high as 1: 6.02.<sup>[4]</sup> Another study by Gupta M et al also reported higher

male to female ratio that is, 1:6.35.<sup>[5]</sup> The female predominance suggests that hormonal factors may be involved and the literature also says that there can be biological changes occurring during pregnancy which may increase the risk.<sup>[6]</sup> Right side neck swelling was more commonly seen while only 4.7% of cases showed midline swelling. Similar observation was seen by Pandey AK et al.<sup>[7]</sup>

For the FNAC of the papillary carcinoma thyroid, the sensitivity was 83.3%, specificity was 100%, PPV was 100%, NPV was 98.7% and accuracy was 98.8%. Jino IJ found in his study that sensitivity, specificity, PPV, NPV of FNAC for papillary carcinoma thyroid was 73%, 98%, 90% and 96% respectively.<sup>[8]</sup>

In this study, FNAC detected pleomorphic adenoma. The sensitivity was 100%, specificity 97.1%, PPV 88.2% and NPV was 100% while accuracy was 97.6%. Gudmundsson JK et al did FNAC in salivary gland masses. They found that FNAC results did not correlate with histology in 6.4% cases. The sensitivity and specificity of FNAC was 73% and 97%. The PPV was 73% and NPV was 97%. The kappa statistic for the degree of agreement between FNAC and histological results was 0.94. The overall accuracy of FNAC was 95%.<sup>[9]</sup> For goiter the sensitivity was 77.8%, specificity was 100%, PPV was 100% and NPV was 94.3%. The accuracy of FNAC for goiter was 95.2%.

**Table 4: Comparison of sensitivity, specificity, PPV and NPV of FNAC in thyroid lesions with other studies.**

Study Group	Sensitivity	Specificity	PPV	NPV
Arda et al. <sup>[10]</sup>	100%	95%	-	-
Haberal et al. <sup>[11]</sup>	92.6%	91.6%	-	-
Sinna et al. <sup>[12]</sup>	92.8%	94.2%	94.9%	91.8%
Saraf et al. <sup>[13]</sup>	72.3%	86.6%	-	-
Saldanha et al. <sup>[14]</sup>	72%	93.5%	78.3%	91.1%
Cap J et al. <sup>[15]</sup>	65-98%	72-100%	34-100%	83-100%
Present study	77.8%	100%	100%	94.3%

The main objective of FNAC is to identify thyroid nodules that can safely be left in situ, excluding carcinoma. Before the introduction of FNA, patients with solid, cold, and/or single nodules had been candidates for surgery. In practice, diagnosis based on FNA has led to a substantial reduction in the number of patients sent to surgery.<sup>[10]</sup>

Haberal AN et al showed that follicular cells that exhibit some of the features of papillary carcinoma could be observed in a cytology slide of Hashimoto's thyroiditis, leading to a diagnostic pitfall. In addition, cellularity and overlapping cytological criteria in hyperplasia might lead to a false diagnosis.<sup>[11]</sup> Saraf et al found a low sensitivity of FNAC for malignancy with no false positive. He found possible reasons for inability of FNAC to correctly diagnose malignant lesions as sampling error, harvesting of inflammatory cells or necrotic tissue.<sup>[13]</sup> Cap J et al found in their study that specificity and PPV are low when fine needle aspiration biopsy results are divided into two categories only and when only suspicious/malignant fine needle aspiration biopsies with subsequent malignant histology are considered to be true positive.<sup>[15]</sup>

## CONCLUSION

It can be summarised from this study that FNAC can be confidently taken as a primary diagnostic tool by an ENT specialist. FNAC is a sensitive, specific, and accurate initial diagnostic test for the evaluation of patients with neck swellings. For further confirmation, histopathology can be taken later on.

## REFERENCES

- Dallari S, Gusella PM, Campanella P, Ciommi M, Pantanetti P, Tortato E, Castriotta A. Current usefulness of aspiration cytology (FNAC) in the head and neck diagnosis. *Pathologica*. 2017 Dec;109(4):355-362.
- Abrari A, Ahmad SS, Bakshi V. Cytology in the otorhinolaryngologist's domain - a study of 150 cases, emphasizing diagnostic utility and pitfalls. *Indian J Otolaryngol Head Neck Surg*. 2002 Apr;54(2):107-10.
- Gleeson M, Browning GG, Burton MJ, Clarkre R, Hibbert J, Jones NS, et al. Benign neck disease: infections and swellings. In: Scott Brown's Otorhinolaryngology Head And Neck Surgery. 7TH ed. Great Britain: Hodder Arnold; 2008. p. 1777.
- Kumar A, Bhadouriya SKS, Narain P, Chauhan JPS, Bharti B, Singh J. Comparative study of FNAC and histopathology of thyroid swellings, diagnostic accuracy and role in its management. *Int J Otorhinolaryngol Head Neck Surg* 2017;3:885-92. 9.
- Gupta M, Gupta S, Gupta VB. Correlation of Fine needle Aspiration Cytology with Histopathology in the diagnosis of solitary thyroid nodule. *J Thyroid Res* 2010(2010); Article ID 379051.10.
- Nagarkar R, Roy S, Akheel M, Palwe V, Kulkarni N, Pandit P. Incidence of Thyroid Disorders in India: An Institutional Retrospective Analysis. *Int J Dent Med Spec* 2015;2:19-23.
- Pandey AK, Bhardwaj A, Maithani T, Kishore S, Singh VP. Distributive Analysis of Head and Neck Swellings with Their Cytopathological Correlation. *Int J Otorhinolaryngol Clin* 2016;8(3):89-96.
- Jino IJ, Harold D. FNAC vs Biopsy-Papillary carcinoma Thyroid. *JMSCR* 2018;06:815-17.
- Gudmundsson JK, Ajan A, Abtahi J. The accuracy of fine-needle aspiration cytology for diagnosis of parotid gland masses: a clinicopathological study of 114 patients. *J Appl Oral Sci*. 2016 Nov-Dec;24(6):561-567.
- Arda IS, Yildirim S, Demirhan B, Firat S. Fine needle aspiration biopsy of thyroid nodules. *Arch Dis Child*. 2001 Oct;85(4):313-7.

11. Haberal AN, Toru S, Ozen O, Arat Z, Bilezikçi B. Diagnostic pitfalls in the evaluation of fine needle aspiration cytology of the thyroid: correlation with histopathology in 260 cases. *Cytopathology*. 2009 Apr;20(2):103-8.
12. Sinna EA, Ezzat N. Diagnostic accuracy of fine needle aspiration cytology in thyroid lesions. *J Egypt Natl Canc Inst*. 2012 Jun;24(2):63-70.
13. Saraf A, Gupta S, Manhas A, Kalsotra P, Goswami KC. Fine needle aspiration cytology versus histopathological examination in head and neck lesions. *OSR-JDMS* 2016;15:122-8.
14. Saldanha P, Kannoli FC. Diagnostic pitfalls in the fine needle aspiration cytology of the breast. *MGM J Med Sci [serial online]* 2020 [cited 2021 Mar 19];7:5-9.
15. Cáp J, Ryska A, Rehorková P, Hovorková E, Kerekes Z, Pohnetalová D. Sensitivity and specificity of the fine needle aspiration biopsy of the thyroid: clinical point of view. *Clin Endocrinol (Oxf)*. 1999 Oct;51(4):509-15.

**Copyright:** © the author(s), 2021. It is an open-access article distributed under the terms of the Creative Commons Attribution License (CC BY 4.0), which permits authors to retain ownership of the copyright for their content, and allow anyone to download, reuse, reprint, modify, distribute and/or copy the content as long as the original authors and source are cited.

**How to cite this article:** Kumar M, Haque MT. Diagnostic Accuracy of Fine Needle Aspiration Cytology (FNAC) in the Diagnosis of the Common Neck Swellings. *Ann. Int. Med. Den. Res.* 2021; 7(3):EN07-EN10.

**Source of Support:** Nil, **Conflict of Interest:** None declared